



Original Article



Diagnostic Accuracy of Colour Doppler Ultrasound in Antenatal Diagnosis of Morbidly Adherent Placenta, Taking Operative Finding as Gold Standard

Memoona Khan¹, Naila Nadeem¹, Mina'a Shahid¹, Muhammad Yousaf¹, Saman Shah² and Saira Samnani¹

¹Department of Radiology, Aga Khan University Hospital, Karachi, Pakistan

²Department of Obstetrics and Gynecology, Jinnah Postgraduate Medical Center, Karachi, Pakistan

ARTICLE INFO

Keywords:

Color Doppler, Morbidly Adherent Placenta, Antenatal Diagnosis, Diagnostic Accuracy

How to Cite:

Khan, M., Nadeem, N., Shahid, M., Yousaf, M., Shah, S., & Samnani, S. (2025). Diagnostic Accuracy of Colour Doppler Ultrasound in Antenatal Diagnosis of Morbidly Adherent Placenta, Taking Operative Finding as Gold Standard: CDU in Morbidly Adherent Placenta and Taking Operative Finding as Gold Standard. *Pakistan Journal of Health Sciences*, 6(12), 112-118. <https://doi.org/10.54393/pjhs.v6i12.3512>

***Corresponding Author:**

Memoona Khan
Department of Radiology, Aga Khan University Hospital, Karachi, Pakistan
memonakhan@gmail.com

Received Date: 30th September, 2025

Revised Date: 2nd December, 2025

Acceptance Date: 19th December, 2025

Published Date: 31st December, 2025

ABSTRACT

Morbidly adherent placenta (MAP), often linked to prior cesarean delivery, is a serious obstetric condition requiring timely Doppler ultrasound diagnosis despite variable specificity. **Objectives:** To evaluate the diagnostic accuracy of Color Doppler ultrasound (CDUS) for antenatal detection of MAP, using intraoperative findings as the reference standard. **Methods:** This was a comparative analytical study with a retrospective review of patient data conducted in the Department of Diagnostic Radiology at Aga Khan University spanning April to August 2025 and included pregnant women via consecutive sampling identified as being at risk for MAP. Each participant underwent an antenatal ultrasound assessment, and the sonographic findings were subsequently compared with operative findings. Diagnostic indices such as sensitivity, specificity, positive and negative predictive values, as well as overall accuracy, were determined. **Results:** Color Doppler ultrasound exhibited strong diagnostic performance in detecting MAP, achieving a sensitivity of 98.10 % (95% CI: 93.29-99.77) and a specificity of 55.56 % (95% CI: 35.33-74.52). The point receiver operating characteristic (ROC) curve demonstrated an area under the curve (AUC) of 0.89, indicative of excellent discriminatory capacity. Diagnostic accuracies were observed as 90.48% for accreta ($p < 0.001$), 89.19% for increta ($p < 0.001$), and 79.17% for percreta ($p < 0.001$). Subgroup analysis showed the same accuracy in women aged ≤ 35 years (98.08%) and those > 35 years (98.08%). **Conclusions:** Doppler ultrasound showed high diagnostic accuracy for MAP with excellent ROC performance and consistent sensitivity across maternal age and gestational subgroups.

INTRODUCTION

Morbidly adherent placenta (MAP) refers to an abnormal implantation of the placenta in which the chorionic villi invade the uterine wall either partially or completely, encompassing the subtypes placenta accreta, increta, and percreta [1]. Although uncommon, MAP is associated with severe, life-threatening maternal complications and remains a major contributor to emergency obstetric hysterectomy worldwide. In Pakistan, it ranks as the third leading indication for emergency hysterectomy, following uterine rupture and postpartum uterine atony [2, 3]. According to international data from the American College

of Obstetricians and Gynecologists, the incidence of morbidly adherent placenta (MAP), also referred to as placenta accreta spectrum (PAS), is estimated at approximately 1 in 2500 deliveries, though more recent studies report rates ranging from 1 in 2500 to 1 in 1100 deliveries, with maternal mortality reaching up to 10% [1]. The rising global incidence has been closely linked to increasing cesarean delivery rates, with recent estimates indicating a pooled prevalence of about 0.17% worldwide and local hospital-based data showing rates as high as 3 per 1000 deliveries [4]. Placenta accreta accounts for



nearly 80% of PAS cases, increta for about 15%, and percreta for roughly 5% [5, 6]. The most firmly established risk factors include placenta previa and a history of prior cesarean section [7, 8]. Several studies have examined the diagnostic accuracy of color Doppler ultrasound (CDUS) for antenatal detection of MAP. A study conducted in Multan reported a sensitivity of 87.5%, specificity of 98.36%, and overall diagnostic accuracy of 97.1% [9]. Kamankesh *et al.* demonstrated sensitivity and specificity of 97.7% and 86.2%, respectively [10], while Nawab *et al.* reported corresponding values of 85.7% and 83.3% [11]. Similarly, research at Ganga Ram Hospital, Lahore, found MAP in 14.38% of deliveries, with sensitivity, specificity, PPV, NPV, and accuracy of 86.96%, 98.54%, 90.91%, 97.83%, and 98.13%, respectively [12]. However, previous studies, both international and local, showed notable variability in diagnostic performance [10, 12]. Although ultrasound remains the first-line imaging tool for suspected MAP, the absence of standardized diagnostic criteria contributes to inconsistency in accuracy and interpretation, posing challenges in clinical decision-making. In Pakistan, standardized and consistent evidence regarding the diagnostic performance of CDUS for MAP is limited. This gap may lead to delayed recognition or misdiagnosis in high-risk pregnancies. Considering the rising incidence of MAP and its strong association with maternal morbidity and mortality, reliable antenatal diagnostic strategies are essential. Based on existing evidence suggesting the diagnostic potential of ultrasonography in detecting abnormal placentation, this study hypothesizes that color Doppler ultrasound provides high diagnostic accuracy in identifying morbidly adherent placenta (MAP) when compared with intraoperative findings. To test this hypothesis, the study aims to determine the sensitivity, specificity, positive predictive value, negative predictive value, and overall diagnostic accuracy of color Doppler ultrasound for the antenatal detection of MAP. The results are expected to inform gynecologists and radiologists on the appropriate application of ultrasound in suspected cases, improve early diagnosis, and ultimately help reduce maternal morbidity and mortality.

In Pakistan, locally standardized and consistent evidence regarding the performance of CDUS in detecting MAP remains limited. This lack of reliable local data may contribute to delayed diagnosis and suboptimal peripartum management. This study aimed to evaluate the diagnostic accuracy of color Doppler ultrasound for antenatal detection of morbidly adherent placenta using intraoperative findings as the reference standard.

METHODS

This comparative analytical study with a retrospective review was conducted in the Department of Diagnostic

Radiology at Aga Khan University Hospital, Karachi, from April to August 2025. The sample size was calculated using previously reported diagnostic parameters, assuming a sensitivity of 85.7% and specificity of 83.3% as reported by Nawab *et al.* [11], and a prevalence of Placental adherence of 36.4% based on Elbery *et al.* [13]. With a 10% margin of error and a 95% confidence level, the minimum required sample size was estimated to be 132 participants, calculated using an online sample size calculator developed by Arifin (<https://wnarifin.github.io/ssc/ssnsp.html>), which is specifically designed for studies evaluating sensitivity and specificity through consecutive sampling. Cases were identified from the hospital's record and all cases that met the predefined inclusion criteria, antenatal suspicion of MAP on Doppler ultrasound, and subsequent operative confirmation at delivery, were included until the required sample size was achieved. Eligible participants were women aged 18–49 years with suspected placental adherence, identified based on third-trimester bleeding or pelvic pain. On color Doppler ultrasound, morbidly adherent placenta (MAP) was diagnosed according to established sonographic criteria, including loss of the utero-placental clear zone, disruption of the serosa-bladder interface, and the presence of turbulent placental lacunae with high-velocity flow [14, 15]. Intraoperative confirmation was established when direct visualization of villous attachment to or invasion of the myometrium was observed. Participants with gestational diabetes, chronic hypertension, cardiovascular disease, or other systemic comorbidities were excluded to minimize potential confounding effects on placental vascularity and Doppler flow patterns. This design-based exclusion was applied during participant selection to ensure diagnostic uniformity. All other demographic variables (maternal age, parity, gravidity, and gestational age) were analyzed descriptively to assess potential distributional differences across diagnostic categories. After obtaining Ethical Review Committee (ERC) approval (Reference No: 2025-10604-33865) and written informed consent from the Institutional Review Committee (IRC), baseline demographic and clinical data were collected from patient records and structured interviews at the time of the ultrasound examination. All Doppler assessments were performed using a GE Voluson E8 ultrasound system (GE Healthcare, Chicago, IL, USA) equipped with a 2–5 MHz curvilinear transducer. Standardized scanning parameters included a pulse repetition frequency (PRF) of 0.9–1.2 kHz, a wall filter optimized for low-flow sensitivity, and color gain adjusted just below the noise threshold to enhance visualization of placental vascularity. All sonographic and clinical findings were recorded on a structured proforma immediately after each examination, with operative

confirmation obtained at delivery for diagnostic correlation. Data were analyzed using SPSS version 26.0, with quantitative variables reported as mean ± SD or median (IQR) and categorical variables as frequencies and percentages. Diagnostic accuracy of Doppler was determined using a 2 × 2 contingency table to calculate sensitivity, specificity, PPV, NPV, and overall accuracy based on true positive, false positive, true negative, and false negative results. Receiver Operating Characteristic (ROC) curve analysis was performed to evaluate the discriminative ability of color Doppler ultrasound in detecting MAP. The area under the curve (AUC) with 95% confidence intervals was computed using the nonparametric DeLong method. Statistical significance for AUC values was determined using the SPSS ROC Curve function (Analyze → ROC Curve). Effect modifiers such as age, gestational age, parity, gravida, booking status, previous cesarean section, and family history of MAP were controlled through stratification, with post-stratification diagnostic accuracy recalculated. Associations were determined using the chi-square test, with p<0.05 considered statistically significant.

RESULTS

The mean age of study participants was 36.21 ± 5.07 years. Age distribution was evenly divided, with 66 (50.0%) of women aged ≤35 years and 66 (50.0%) older than 35 years. The median gestational age was 36 weeks (IQR: 4.00); among them, 81 (61.36%) delivered at <37 weeks, while 51 (38.64%) delivered beyond 37 weeks of gestation. Regarding parity, the majority were multiparous (≥2 births, 111 (84.1%), while 11 (8.3%) were nulliparous and 10 (7.6%) were primiparous. Gravida was equally distributed between multigravida (G2–G4, 66 (50.0%) and grand multigravida (>5, 66(50.0%). A history of previous cesarean

section was reported in 103 (78.0%) of women, compared to 29 (22.0%) without such a history. Finally, only 9 (6.8%) had a positive family history, whereas the vast majority, 123 (93.2%), reported no relevant family history. The study presents detailed baseline demographic and clinical characteristics of the study cohort (Table 1).

Table 1: Baseline Characteristics of the Study Population

Characteristics		Descriptive Statistics, n (%)
Age (Mean ± SD)		36.21 ± 5.07
Age Groups	≤35 Years	66 (50.00%)
	>35 Years	66 (50.00%)
Gestational Week Median (IQR)		– 36 (4.00%)
Gestational Groups	<37 Weeks	81 (61.36%)
	>37 Weeks	51 (38.64%)
Parity	Nulliparous Parity=0	11 (8.30%)
	Primiparous Parity=1	10 (7.60%)
	Multiparous Parity= >2	111 (84.1%)
Gravida	Multigravida (G2–G4)	66 (50.00%)
	Grand Multigravida (>5)	66 (50.00%)
Residence	Urban	99 (75.00%)
	Rural	33 (25.00%)
Booking status	Yes	93 (70.50%)
	No	39 (29.50%)
Previous C Section	Yes	103 (78.0%)
	No	29 (22.0%)
Family History	Yes	9 (6.80%)
	No	123 (93.20%)

Ultrasound identified 15 true negatives (55.6%), with 2 false positives (1.9%), and detected 103 true positives (98.1%), with 12 false negatives (44.4%). Sensitivity was 98.10%, specificity 55.56%, PPV 89.57%, NPV 88.24%, and overall accuracy 89.39% (p<0.001) (Table 2).

Table 2: Diagnostic Performance of Ultrasound for the Detection of MAP Compared with Operative Findings

Category	MAP–Operative Findings		Sensitivity (95% CI)	Specificity (95% CI)	PPV (95% CI)	NPV (95% CI)	Overall Accuracy (95% CI)	p-value
	Absent	Present						
MAP on CDUS	Absent	15 (55.60%)	98.10 (93.29–99.77)	55.56 (35.33–74.52)	89.57 (84.91–92.91)	88.24 (64.60–96.86)	89.39 (82.85–94.08)	<0.001
	Present	12 (44.40%)						

Note: Subgroups with small sample sizes (e.g., n=2 false positives and n=12 false negatives) yield wide confidence intervals and should be interpreted with caution due to limited precision and potential instability of estimates.

The results present the diagnostic performance of ultrasound for placenta accreta, increta, and percreta. For placenta accreta, sensitivity was 90.48% and specificity 91.80%, with a PPV of 88.37%, NPV 93.33%, and overall accuracy 91.26% (p<0.001). For placenta increta, sensitivity was 89.19% and specificity 90.91%, with PPV 84.62%, NPV 93.75%, and accuracy 90.29% (p<0.001). For placenta percreta, sensitivity was 79.17% and specificity 97.47%, with PPV 90.48%, NPV 93.90%, and accuracy 93.20% (p<0.001) (Table 3).

Table 3: Diagnostic Accuracy of Ultrasound in Detecting Different Types of MAPS Compared with Operative Findings

MAP on CDUS	MAP–Operative Findings		Sensitivity (95% CI)	Specificity (95% CI)	PPV (95% CI)	NPV (95% CI)	Overall Accuracy (95% CI)	p-value
	Absent	Present						
Acreta	Absent	56 (91.80%)	90.48 (77.38–97.34)	91.80 (81.90–97.28)	88.37 (76.54–94.65)	93.33 (84.60–97.27)	91.26 (84.06–95.93)	<0.001
	Present	5 (8.20%)						

Increta	Absent	60 (90.90%)	4 (10.80%)	89.19 (74.58-96.97)	90.91 (81.26-96.59)	84.62 (71.78-92.24)	93.75 (85.56-97.43)	90.29 (82.87-95.25)	<0.001
	Present	6 (9.10%)	33 (89.20%)						
Percreta	Absent	77 (97.50%)	5 (20.80%)	79.17 (57.85-92.87)	97.47 (91.15-99.69)	90.48 (70.43-97.43)	93.90 (87.58-97.11)	93.20 (86.50-97.22)	<0.001
	Present	2 (2.50%)	19 (79.20%)						

Findings show high ultrasound sensitivity (>96%) across subgroups, with specificity ranging widely from 0% to 100%. Overall accuracy exceeded 86% in most categories, while p-values were statistically significant (<0.05) for all subgroups except family history (p=0.236)(Table 4).

Table 4: Diagnostic Accuracy of Ultrasound According to Maternal and Clinical Characteristics

Category	Subgroups	Sensitivity (95% CI)	Specificity (95% CI)	PPV (95% CI)	NPV (95% CI)	Accuracy (95% CI)	P-value
Age Groups (Years)	≤35 (n=26)	98.08 (89.74-99.95)	64.29 (35.14-7.24)	91.07 (83.46-95.37)	90.00 (55.41-98.49)	90.91 (81.26-96.59)	<0.001
	>35 (n=25)	98.08 (89.74-99.95)	46.15 (19.22-74.87)	87.93 (81.48-92.35)	85.71 (44.12-97.85)	87.69 (77.18-94.53)	<0.001
Gestational (Weeks)	<37 (n=81)	98.39 (91.34-99.96)	57.89 (33.50-79.75)	88.41 (81.81-92.82)	91.67 (60.26-8.76)	88.89 (79.95-94.79)	<0.001
	>37 (n=51)	97.67 (87.71-99.94)	50.00 (15.70-84.30)	91.30 (83.93-95.46)	80.00 (33.83-96.90)	90.20 (78.59-96.74)	<0.001
Gravida	Multigravida (n=66)	100 (93.40-100)	58.33 (27.67-84.83)	91.53 (84.68-95.47)	100 (59.04-100)	92.42 (83.20-97.49)	<0.001
	G-Multigravida (n=66)	96.08 (86.54-99.52)	53.33 (26.59-78.73)	87.50 (80.25-92.34)	80.00 (48.69-94.40)	86.36 (75.69-93.57)	<0.001
Parity	Nulliparous-P (n=11)	100 (69.15-100)	100 (2.50-100)	100 (69.15-100)	100 (2.50-100)	100 (71.51-100)	<0.001
	Primiparous-P (n=10)	100 (66.37-100)	0.00 (0.00-100)	90.00 (90.00-90.00)	—	90.00 (55.50-99.75)	—
	Multiparous-P (n=111)	97.67 (91.85-99.72)	56.00 (34.93-75.60)	88.42 (83.05-92.25)	87.50 (63.01-96.64)	88.29 (80.81-93.61)	<0.001
Residence	Urban (n=99)	98.70 (92.98-99.97)	50.00 (28.22-71.78)	87.36 (81.97-91.31)	91.67 (60.02-98.77)	87.88 (79.78-93.58)	<0.001
	Rural (n=33)	96.43 (81.65-99.91)	80.00 (28.36-99.94)	96.43 (82.37-99.36)	80.00 (35.72-96.64)	93.94 (79.77-99.26)	<0.001
Booking-Status	Booked (n=93)	98.59 (92.40-99.96)	59.09 (36.35-79.29)	88.61 (84.29-98.95)	92.86 (84.29-98.95)	89.25 (81.11-94.72)	<0.001
	Un-Booked (n=39)	97.06 (84.67-99.93)	40.00 (5.27-85.34)	91.67 (18.00-94.80)	66.67 (18.00-94.80)	89.74 (75.78-97.13)	0.004
Previous C Section	Yes (n=103)	97.56 (91.47-99.70)	61.90 (38.44-81.89)	90.91 (85.27-94.53)	86.67 (61.36-96.38)	90.29 (82.87-95.25)	<0.001
	No (n=29)	100 (85.18-100)	33.33 (4.33-77.72)	85.19 (76.56-91.01)	100 (15.81-100)	86.21 (68.34-96.11)	0.004
Family History	Yes (n=9)	100 (47.82-100)	25.00 (0.63-80.59)	62.50 (48.63-74.59)	100 (2.50-100)	66.67 (29.93-92.51)	0.236
	No (n=123)	98.00 (92.96-99.76)	60.87 (38.54-80.29)	91.59 (86.73-94.78)	87.50 (63.07-96.63)	91.06 (84.56-95.45)	<0.001

The ROC curve was constructed using the observed operating point (sensitivity = 98.10%, specificity = 55.56%), connecting the coordinates (0, 0) to the operating point and subsequently to (1, 1). The resulting AUC was 0.89, reflecting good diagnostic accuracy. The shaded region illustrates the 95%CI, while the diagonal dashed line represents the line of no discrimination (Figure 1).

ROC Curve for MAP on Ultrasound vs Operative Findings

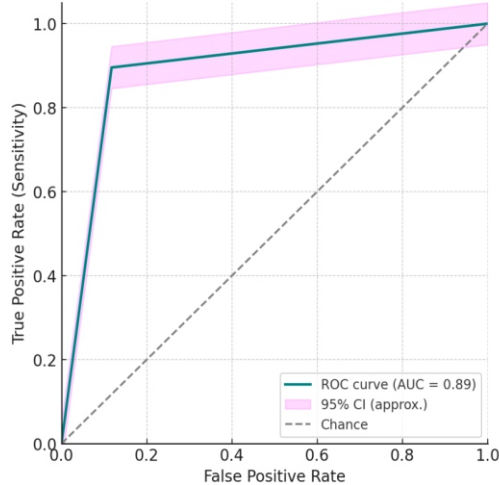


Figure 1: Receiver Operating Characteristic (ROC) Curve Depicting Diagnostic Performance of Ultrasound in Detecting MAP

DISCUSSION

Ultrasound remains the cornerstone for the prenatal diagnosis of abnormal placental adherence, owing to its wide availability, non-invasive nature, and real-time assessment of placental morphology and vascularity. It demonstrates consistently high sensitivity in detecting abnormal placental adherence; however, its specificity can vary considerably depending on operator expertise, equipment quality, and the diagnostic criteria applied. In our study, the approximated ROC operating point revealed a sensitivity of approximately 87.3%, specificity of 86.96%, and an AUC of ~0.89, aligning well with recent systematic meta-analyses that report pooled ultrasound sensitivity in the 86% range (95% CI: 78-92%) and specificity around 63% (95% CI: 55-70%) [16]. Nonetheless, the nearly 98% sensitivity observed in our diagnostic comparison of ultrasound versus operative findings exceeds typical pooled results. This elevated performance likely reflects our cohort's high prevalence of PAS risk factors, primarily previous cesarean sections (78%), which can artificially inflate predictive metrics [17]. Additionally, our use of an imaging procedure performed by trained sonographers may contribute to this superior accuracy, consistent with data showing that ultrasound scoring systems improve diagnostic reliability [18, 19]. In contrast to the high

specificity reported in previous studies, such as Kamankesh *et al.* (86.2%) [10], Jauniaux *et al.* ($\geq 90\%$) [20], and Nawab *et al.* (83.3%) [11]. The present study demonstrated a lower specificity (55.6%). This discrepancy may be attributed to the high prevalence of risk factors, particularly previous cesarean deliveries, in our cohort, which increased the likelihood of false-positive interpretations. Furthermore, the absence of a standardized scoring system, as emphasized in the FIGO guidelines [20], may have led to overdiagnosis based on isolated sonographic markers (e.g., placental lacunae, loss of clear zone). Operator vigilance in a high-risk referral setting may also have contributed to prioritizing sensitivity over specificity, thereby reducing the latter. Structured scoring systems, such as those evaluated by Zlotin *et al.* demonstrated remarkable accuracy, achieving AUC values of around 0.93, with pooled sensitivity and specificity exceeding 85% [19]. Peng *et al.* systematic review supports these findings, noting optimal performance in studies utilizing scoring frameworks [21]. These results affirm the advantages of standardized imaging protocols in ultrasound diagnostics. Although MRI offers comparable diagnostic performance with reported sensitivity and specificity in the high 80s to low 90s, its principal value lies in clarifying placental invasion in posterior or lateral PAS, locations where ultrasound has limitations [14, 22]. This supports the widely accepted clinical strategy of using ultrasound as the initial modality and reserving MRI for equivocal or anatomically challenging cases. The specificity variation observed across clinical subgroups, particularly low specificity in primiparous or family-history subgroups, likely stems from small sample sizes in these categories. Such small numbers ($n < 20$) result in wide confidence intervals and unstable estimates, a known limitation in single-center observational research [17]. Future investigations with larger, more diverse cohorts would help strengthen the reliability of subgroup analyses and improve generalizability. Overall, the high sensitivity and AUC reported in our results substantiate ultrasound's continued role as an effective primary diagnostic tool for PAS, particularly within high-risk populations. Nevertheless, integrating MRI for select cases and adopting structured ultrasound scoring systems are sound approaches to optimize prenatal risk stratification and facilitate surgical planning [18, 23].

The study's diagnostic estimates may be influenced by the high prevalence of PAS risk factors, particularly previous cesarean delivery, which can inflate sensitivity and reduce specificity. Additionally, lack of a standardized ultrasound scoring system and small subgroup sizes may have led to variability in specificity and unstable subgroup estimates. Future studies should focus on multicenter, prospective efforts to validate ultrasound scoring systems across

diverse populations, and on establishing standardized diagnostic definitions for PAS. Several large-scale collaborative studies have evaluated the diagnostic performance of scoring systems and imaging criteria for PAS [21, 24]. They provide the evidence base for why future multicenter, prospective, and standardized research is needed.

CONCLUSIONS

Color Doppler ultrasound demonstrated high sensitivity and strong overall diagnostic accuracy for detecting morbidly adherent placenta. While specificity showed moderate variability, the test maintained consistent performance across maternal age and gestational subgroups. These findings confirm the reliability of Doppler ultrasound as an effective antenatal diagnostic tool for a morbidly adherent placenta.

Authors' Contribution

Conceptualization: MK

Methodology: NN, MS, MY, SS¹, SS²

Formal analysis: MK

Writing and Drafting: MK, NN

Review and Editing: MK, NN, MS, MY, SS¹, SS²

All authors approved the final manuscript and take responsibility for the integrity of the work

Conflicts of Interest

All the authors declare no conflict of interest.

Source of Funding

The author received no financial support for the research, authorship and/or publication of this article.

REFERENCES

- [1] Hasan AA, Hasan JA, Khan AA. Management and Maternal Outcome in Morbidly Adherent Placenta. *Journal Surgery of Pakistan*. 2009 Oct; 14(4): 166.
- [2] Derman AY, Nikac V, Haberman S, Zelenko N, Opsha O, Flyer M. MRI of Placenta Accreta: A New Imaging Perspective. *American Journal of Roentgenology*. 2011 Dec; 197(6): 1514-21. doi: 10.2214/AJR.10.5443.
- [3] De la Cruz CZ, Thompson EL, O'Rourke K, Nembhard WN. Cesarean Section and the Risk of Emergency Peripartum Hysterectomy in High-Income Countries: A Systematic Review. *Archives of Gynecology and Obstetrics*. 2015 Dec; 292(6): 1201-15. doi: 10.1007/s00404-015-3790-2.
- [4] Amjad A, Imran A, Shahram N, Zakar R, Usman A, Zakar MZ *et al.* Trends of Caesarean Section Deliveries in Pakistan: Secondary Data Analysis from Demographic and Health Surveys, 1990-2018. *BioMed Central Pregnancy and Childbirth*. 2020 Dec; 20(1): 753. doi: 10.1186/s12884-020-03457-y.

- [5] Matsuzaki S, Mandelbaum RS, Sangara RN, McCarthy LE, Vestal NL, Klar M et al. Trends, Characteristics, and Outcomes of Placenta Accreta Spectrum: A National Study in the United States. *American Journal of Obstetrics and Gynecology*. 2021 Nov; 225(5): 534-e1. doi: 10.1016/j.ajog.2021.04.233.
- [6] Huma ZE, Zia U, Sadiq A, Saleem A, Noreen S, Aslam A. Maternal and Neonatal Health Outcomes in Placenta Accreta: Short-Term Morbidity and Long-Term Neurodevelopmental Impacts: Placenta Accreta: Short-Term Morbidity and Long-Term Neurodevelopmental Impacts. *Pakistan Journal of Health Sciences*. 2025 Feb; 224-9. doi: 10.54393/pjhs.v6i2.2223.
- [7] Choi SJ, Song SE, Jung KL, Oh SY, Kim JH, Roh CR. Antepartum Risk Factors Associated with Peripartum Cesarean Hysterectomy in Women with Placenta Previa. *American Journal of Perinatology*. 2008 Jan; 25(01): 037-41. doi: 10.1055/s-2007-1004834.
- [8] Khalid D, Noreen A, Javed AM, Zahra M, Gul M, Shakir A. Diagnostic Accuracy of Color Doppler Ultrasound in Antenatal Diagnosis of Morbidly Adherent Placenta, Taking Operative Findings of Caesarean Section as Gold Standard. *Pakistan Journal of Medical and Health Sciences*. 2016 Apr; 10(2): 478-81.
- [9] Khatoun H, Naz A, Mushtaq N, Aahuja K. To Assess the Diagnostic Accuracy of Color Doppler Ultrasound in Antenatal Diagnosis of Placenta Accreta Taking Histopathology as Gold Standard. *The Professional Medical Journal*. 2020 Dec; 27(12): 2681-5. doi: 10.29309/TPMJ/2020.27.12.5553.
- [10] Kamankesh R, Hanafi MG, Bakhtiari Z, Masihi S. Evaluation of the Sensitivity and Specificity Of 2D and Color Doppler Sonography in the Detection of Placenta Accreta in Pregnant Women. *Journal of Family Medicine and Primary Care*. 2020 Feb; 9(2): 1009-12. doi: 10.4103/jfmpc.jfmpc_867_19.
- [11] Nawab K, Naveed S, Khan M. Diagnostic Accuracy of Ultrasound (USG) and Magnetic Resonance Imaging (MRI) in Prenatal Diagnosis of Placenta Accreta Taking Operative Findings as Gold Standard. *Pakistan Journal of Radiology*. 2017 Oct; 27(4).
- [12] Tasheer AA. Diagnostic Accuracy of Doppler Ultrasound for Antenatal Detection of Morbidly Adherent Placenta. *Journal of Fatima Jinnah Medical University*. 2014; 8(1).
- [13] Elbery SA, Mahmoud MA, Mansour AE, Rashed MF, Salem HE. Incidence and Risk Factors of Morbidly Adherent Placenta in Cases with Previous Caesarean Section in Benha University Hospital. *Benha Journal of Applied Sciences*. 2020 Jul; 5(4 part (2)): 341-6. doi: 10.21608/bjas.2020.136386.
- [14] Tsankova M, Kirkova M, Geshev N. Placenta Accreta Spectrum: Ultrasound Diagnosis and Clinical Correlation. *Biotechnology and Biotechnological Equipment*. 2023 Nov; 37(1): 2287238. doi: 10.1080/13102818.2023.2287238.
- [15] Mohamed EA, Ahmed RA, Metwali NY, Timraz JH, Mohamed A, Mansour HA. Accuracy of Ultrasound in Prediction of Abnormal Placental Adherence: A Systematic Review and Meta-Analysis. *American Journal of Obstetrics and Gynecology Global Reports*. 2025 May; 5(2): 100467. doi: 10.1016/j.xagr.2025.100467.
- [16] Hessami K, Horgan R, Munoz JL, Norooznejhad AH, Nassr AA, Fox KA et al. Trimester-Specific Diagnostic Accuracy of Ultrasound for Detection of Placenta Accreta Spectrum: Systematic Review and Meta-Analysis. *Ultrasound in Obstetrics and Gynecology*. 2024 Jun; 63(6): 723-30. doi: 10.1002/uog.27606.
- [17] Maged AM, El-Mazny A, Kamal N, Mahmoud SI, Fouad M, El-Nassery N et al. Diagnostic Accuracy of Ultrasound in the Diagnosis of Placenta Accreta Spectrum: Systematic Review and Meta-Analysis. *BioMed Central Pregnancy and Childbirth*. 2023 May; 23(1): 354. doi: 10.1186/s12884-023-05675-6.
- [18] Chen Q, Shen K, Wu Y, Wei J, Huang J, Pei C. Advances in Prenatal Diagnosis of Placenta Accreta Spectrum. *Medicina*. 2025 Feb; 61(3): 392. doi: 10.3390/medicina61030392.
- [19] Zlotin MP, Sharabi-Nov A, Meiri H, Revivo PE, Melcer Y, Maymon R et al. Clinical-Sonographic Scores for the Screening of Placenta Accreta Spectrum: A Systematic Review and Meta-Analysis. *American Journal of Obstetrics and Gynecology Maternal-Fetal Medicine*. 2024 Aug; 6(8): 101369. doi: 10.1016/j.ajogmf.2024.101369.
- [20] Jauniaux E, Ayres-de-Campos D, Langhoff-Roos J, Fox KA, Collins S, Duncombe G et al. FIGO Classification for the Clinical Diagnosis of Placenta Accreta Spectrum Disorders. *International Journal of Gynecology and Obstetrics*. 2019 Jul; 146(1): 20-4. doi: 10.1002/ijgo.12761.
- [21] Peng X, Tan X, Wu Z. Prenatal Ultrasound Scoring in Diagnosis and Postpartum Outcomes Prediction for Placenta Accreta Spectrum (PAS): A Systematic Review. *BioMed Central Pregnancy and Childbirth*. 2024 Dec; 24(1): 846. doi: 10.1186/s12884-024-07076-9.
- [22] AbdelAziz S, El-Goly NA, Maged AM, Bassiouny N, El-Demiry N, Shamel A. Diagnostic Accuracy of Magnetic Resonance Imaging in the Diagnosis of Placenta Accreta Spectrum: A Systematic Review and Meta-Analysis. *Maternal-Fetal Medicine*. 2025 Jan; 7(01): 15-21. doi: 10.1097/FM9.0000000000000241.
- [23] Zhang J, Li H, Feng D, Wu J, Wang Z, Feng F. Ultrasound Scoring System for Prenatal Diagnosis of Placenta

Accreta Spectrum. *BioMed Central Pregnancy and Childbirth*. 2023 Aug; 23(1): 569. doi: 10.1186/s12884-023-05886-x.

- [24] Li C, Chen Y, Gao Y, Duan Y. Ultrasound Versus Magnetic Resonance Imaging Features in Diagnosing Placenta Accreta: A Systematic Review and Meta-Analysis. *European Journal of Radiology*. 2025 Jun; 187: 112108. doi: 10.1016/j.ejrad.2025.112108.