



Original Article

Reliability of Mandibular Plane in Determining Gonial Angle on Lateral Cephalogram

Maleeha Mustafa¹, Asma Shafique¹ and Abir Arif Syed¹

¹Department of Orthodontics, Lahore Medical and Dental College, Lahore, Pakistan

ARTICLE INFO

Keywords:

Lateral Cephalogram, Mandible, Orthopantomography, Reliability

How to Cite:

Mustafa, M., Shafique, A., & Syed, A. A. (2025). Reliability of Mandibular Plane in Determining Gonial Angle on Lateral Cephalogram: Mandibular Plane in Gonial Angle on Lateral Cephalogram. *Pakistan Journal of Health Sciences*, 6(5), 13-17. <https://doi.org/10.54393/pjhs.v6i5.3028>

*Corresponding Author:

Maleeha Mustafa
Department of Orthodontics, Lahore Medical and Dental College, Lahore, Pakistan
maleeha.mustafa@ubas.edu.pk

Received date: 14th February, 2025

Revised date: 2nd May, 2025

Acceptance date: 8th May, 2025

Published date: 31st May, 2025

ABSTRACT

Gonial angle is an essential cephalometric indicator used in orthodontic diagnosis and treatment planning. The precise evaluation of the gonial angle is vital for understanding mandibular growth patterns and formulating efficient treatment strategies. **Objectives:** To assess the mean gonial angle according to the three mandibular planes, Tweed's, Steiner's, and Downs', on lateral Cephalogram and panoramic radiograph for Orthodontic Diagnosis and Treatment Planning. **Methods:** The Descriptive Cross-Sectional Survey was performed in the Orthodontics Department, Lahore Medical and Dental College (LMDC). Lateral Cephalogram and Ortho-pantomography (OPG) of 100 patients were used. The Gonial angle was assessed on the OPG by drawing a tangent to the lower border of the mandible and the most distal point of the ascending ramus and condyle. On the Lateral Cephalogram, however, the Gonial angle was measured by drawing a tangent to the posterior border of the ramus and making three mandibular planes according to Down, Tweed, and Steiner analysis. The Gonial angle assessed on the lateral Cephalogram was compared to that on OPG to evaluate which plane provides the gonial angle value closest to that obtained on OPG. All data were collected and recorded on a Performa. **Results:** The mean gonial angle on lateral Cephalogram was $123.06 \pm 6.80^\circ$, 121.5 ± 6.40 , and 123.77 ± 6.43 using Tweeds, Steiner's, and Downs mandibular planes, respectively, and on OPG, the mean gonial angle was 123.45 ± 6.89 . **Conclusions:** It was concluded that Down's mandibular plane provides the Gonial angle reading that is closest to that found on OPG.

INTRODUCTION

Radiographs play a crucial role in orthodontic diagnosis and treatment planning that ensures precise diagnosis, guides the development of personalized treatment plans, and monitors progress throughout orthodontic therapy. Understanding the importance of these diagnostic tools is key to achieving optimal outcomes in orthodontics. The two most commonly used radiographs in orthodontics are the Orthopantomogram (OPG) and lateral cephalogram [1]. Orthopantomography (OPG) is an important research and clinical tool for analyzing teeth, their axial inclinations, supporting bone levels, fractures, ankyloses, sinuses, and the shape of the condyles [1]. It provides the chance to evaluate the existence and non-existence of any pathology or the overall health of the surrounding teeth and oral tissues [2]. Absence superimposition of right and left side

structures with moderately reduced radiation exposure makes it a fundamental norm of care for Orthodontic diagnosis and treatment planning [3, 4]. A lateral cephalogram is another radiographic technique utilized for quantitative investigations and measurements [5]. Certain landmarks that can be anatomic or derived are used to assess the horizontal and vertical relationship of maxillary and mandibular dentition and their respective alveolar processes [6, 7]. The gonial angle is one of the main variables used to assess vertical growth patterns [8], mandibular steepness, mandibular asymmetry [9], and age determination in forensic medicine [10]. Patients with a downward and posterior rotation of the mandible tend to have an increased gonial angle, and these individuals are classified as having a "high-angle" profile. In contrast, the

angle is decreased in patients with forward and upward rotation and is termed "low angle" cases. The Gonial angle is formed at the convergence of mandibular and ramal plane. In the lateral Cephalogram, the Ramal plane is taken as a straight line at 90 degrees to the posterior aspect of the ramus. However, the mandibular plane can be defined in three different ways [3, 6], as proposed by various researchers: Tweed's method (using a tangent to the inferior margin of the mandible) [11], Steiner's method (drawing a line from Gonion to Gnathion) [12], and Down's method (drawing a line from Gonion to Menton) [13]. Irrespective of the method used for constructing the mandibular plane, Gonial angle measurement is questionable on lateral Cephalograms due to the overlapping of right and left sides [14]. However, the Gonial angle measurement on an OPG (Orthopantomogram) is relatively convenient as we can appreciate the right and left rami individually, avoiding any overlapping or superposing of anatomical landmarks that frequently occur in lateral cephalograms [15]. Several researchers have made the comparison between the two forms of radiographs for analyzing the Gonial angle [16]; some studies suggest that OPG is useful in providing a broad view of information on the dental and skeletal structures including the vertical aspect of craniofacial structure but it is less definitive for detailed and accurate analysis in comparison with lateral Cephalogram [13].

Although both OPG and lateral cephalogram are widely used for gonial angle assessment, inconsistency exists regarding which mandibular plane on cephalograms best correlates with OPG measurements. Additionally, limited evidence is available comparing different cephalometric methods with OPG for accurate and reliable gonial angle evaluation. This study aims to investigate which Mandibular plane intended for calculating the Gonial angle on the Lateral Cephalogram corresponds best with the Gonial angle evaluated on the OPG.

METHODS

A descriptive cross-sectional study was carried out from August 09 2021 to February 8, 2022, at Lahore Medical and Dental College. The study was approved by the ethical review board of Lahore Medical and Dental College (Reference number: LMDC/FD/ 2735/25). Before collecting pre-treatment radiographic records, patient consent was duly taken regarding the potential risks of radiation exposure. A non-probability, consecutive sampling technique was implemented to select 100 radiographs (lateral cephalograms and OPGs) [2] of 41 male and 59 female patients aged 13 to 29 years, from the Orthodontics Department at Lahore Medical and Dental College. The sample size was calculated by Open Epi software. One hundred radiographs are estimated using $\alpha=0.11$, 95% confidence level, and taking expected mean gonial angle as

125.3 ± 5.57 , 132.4 ± 5.74 , 128.37 ± 5.6 and 126.0 ± 7.13 on Steiner's, Tweed's, Downs and OPG, respectively [1]. The principal investigator thoroughly reviewed and verified all patients' clinical records. Radiographs from patients with a prior history of dento-facial surgery, disorders involving craniofacial structures, asymmetry, or a history of trauma were excluded. Lateral Cephalograms were taken while the teeth were in centric occlusion, using a Cephalostat. The x rays were acquired with the Villa Rotograph Evo D OPG system by Villa System Medical. The patients were exposed to a voltage range of 73kv-15ma to 84kv-13ma, following universal protocols while ensuring a natural head position. In the 100 chosen samples, the names were obscured on the radiographs. All lateral cephalometric radiographs were manually traced on acetate paper using a 3H pencil on a transilluminator. A geometrical protractor and a ruler were employed to determine the gonial angle. The gonial angle on the OPG was assessed by drawing a straight line to the base of the mandible and the most distal point of the condyle and ascending ramus [13] on both sides and then taking an average value of the two (Figure 1).

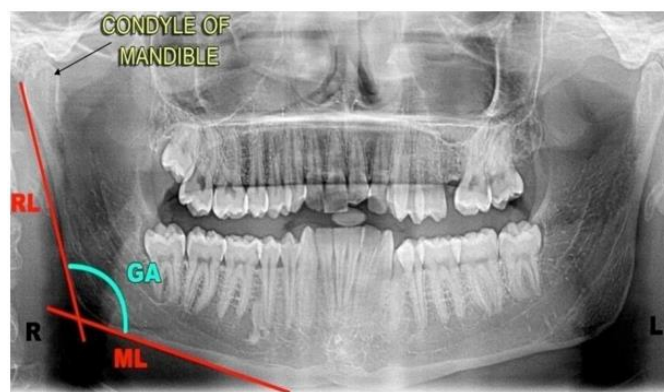

Figure 1: Gonial Angle Measurement on OPG

However, on Lateral Cephalogram, the Gonial angle was determined by depicting a straight line at a 90-degree angle to the posterior border of the ramus and drawing three mandibular planes according to Down [12], Tweed [11], and Steiner [17] analysis (Figure 2).

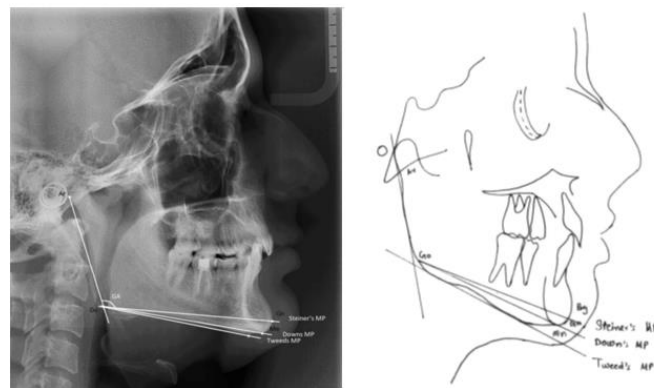


Figure 2: Gonial Angle Measurement on Lateral CEPH

All data were gathered and recorded on the Proforma. The mean and standard deviation (SD) were computed for the

Gonial angle measured on OPG and on lateral Cephalogram through Tweeds, Steiner, and Down's analysis. The statistical analysis was done utilizing SPSS software for Windows (IBM; SPSS, version 20.0). Numerical variables like age and gonial angle were calculated in terms of descriptive statistics. The mean gonial angle on lateral cephalogram using tweeds, steiners and the down mandibular plane and on OPG with standard deviations was calculated. The Kolmogorov-Smirnov and Shapiro-Wilk tests were applied to each variable (mean opg, Tweed, Steiner, and Down), which showed significant p-values ($p < 0.050$), indicating a significant deviation from normality. Non-parametric Spearman's rank correlation was used to measure the degree of correlation between three methods of gonial angle formation on cephalogram with the method on orthopantomogram.

RESULTS

A total of 100 individuals participated in the study, with 41 male and 59 female. The mean age of the individuals was 19.97 ± 4.23 years. Descriptive statistics of age and gender are presented (Table 1).

Table 1: Descriptive Statistics for Age and Gender

Variables	Minimum	Maximum	Mean \pm SD
Age	13.00	29.00	19.97 ± 4.23
Gender Frequency (%)	Male	41%	–
	Female	59%	–

The mean of the gonial angle on lateral cephalogram using Tweeds, Steiner's, and Downs mandibular plane was $123.06 \pm 6.80^\circ$, $121.52^\circ \pm 6.40^\circ$ and $123.77^\circ \pm 6.43^\circ$, respectively. The mean value of the Gonial angle on Orthopantomogram among participants was $123.45^\circ \pm 6.89^\circ$ (Table 2).

Table 2: Descriptive Statistics of Gonial Angle on Lateral Cephalometric Radiograph and Orthopantomogram

Radiograph	Mean \pm SD	
Gender Frequency (%)	Tweed	$123.06 \pm 6.80^\circ$
	Steiner	$121.52^\circ \pm 6.40^\circ$
	Down's	$123.77^\circ \pm 6.43^\circ$
OPG	Mean OPG	$123.45^\circ \pm 6.89^\circ$

Spearman's rank correlation values for gonial angles on OPG and lateral cephalogram using the three different mandibular planes revealed a very strong positive correlation between mean OPG and Down's method ($\rho = 0.924$, $p < 0.001$) (Table 3).

Table 3: Spearman's Correlation Between Mean Gonial Angle On OPG and Lateral Cephalogram (Tweed, Steiner's and Down)

Comparison	Spearman's ρ	Sig. (2-tailed) p-value
Mean OPG vs. Down	0.924	0.000
Mean OPG vs. Tweed	0.685	0.000
Mean OPG vs. Steiner	0.285	0.004

**Correlation was significant at the 0.010 level (2-tailed).

*Correlation was significant at the 0.050 level (2-tailed)

DISCUSSION

Implant research on jaw rotations conducted by Bjork and coworkers in 1960 suggested that the rotation of the mandible during the growth period results in different vertical facial patterns, including normal, short, and long faces [1]. Gonial angle is one of the most significant cephalometric parameters indicating the facial skeleton's vertical growth pattern and symmetry [2]. The structure and form of the mandible are depicted by the gonial angle, and its numerical value suggests the mandibular growth direction. It also strongly affects the facial profile, lip seal and competence, and angulation of the lower incisors [8]. Moreover, re-evaluating the gonial angle after orthodontic treatment has been completed can provide important information about post-treatment results and stability [5]. Panoramic radiographs, when utilized in orthodontic practice, offer insightful information regarding the gonial angle and have the advantage of visualizing both the right and left angles without superimposition [9]. Upadhyay et al., [14], Hardin et al., [16] and Nadkerny et al., [9] examined the use of panoramic radiography for assessing the gonial angle, and the findings indicated that gonial angle measurements on panoramic radiographs are both accurate and consistent. However, the gonial angle on the lateral Cephalogram is assessed by convergence of a straight line 90 degrees to the Mandible's lower border and posterior ramus [18]. Because of the superimposition of structures in the lateral Cephalogram, it's sometimes hard to identify and determine the gonial angle. Lateral cephalograms provide a distorted view of the gonial angle, making it difficult to obtain accurate measurements for each angle, and are typically considered as a median angle between the right and left gonial angles [14]. The mandibular plane, used for analysing the gonial angle through lateral cephalometry, is horizontal, and three ways to assess the mandibular plane as described by different orthodontists are Tweed's, Steiner's and Down's. Due to the different mandibular planes (Tweed, Steiner's, and Down), there is significant variation in the gonial angle associated with each specific plane used [11]. This study evaluated which gonial angle (obtained from Tweed, Steiner, or Downs mandibular planes) on a lateral cephalogram had a value closest to that obtained on a panoramic radiograph. According to the results of our study, the Down's method showed a very strong positive correlation with the OPG measurement ($\rho = 0.924$, $p < 0.001$), followed by the Tweed method ($\rho = 0.685$, $p < 0.001$) and the Steiner method showed the weakest correlation ($\rho = 0.285$, $p = 0.004$). This concluded that the Down's mandibular plane provides the best correspondence with the gonial angle as measured on the OPG compared to the other two mandibular planes, Steiner's and Tweed's. Our study's result is in contrast with Bibi T's survey [15], which reported an important link between the cephalometric and panoramic values using Tweed's mandibular plane and the gonial angle is defined as

the intersection of two tangents: One tangent along the inferior border of the mandible and the other along the posterior ramus. The disparity in the results with our study could be because in Bibi T's survey, no other mandibular plane was assessed, and the results were based only on Tweed's mandibular plane. Another research carried out by Kundi I, also found a statistically significant mean gonial angle value, measured using the Tweeds mandibular plane on lateral Cephalogram compared with that on an OPG in Class I, Class II, and Class III patients [7]. The research concluded that both lateral cephalometric and panoramic radiographs are reliable methods for measuring the gonial angle in orthodontic patients. However, among the three mandibular planes assessed for determining gonial angles on lateral cephalograms, Tweed's mandibular plane relates better with OPG than Steiner's and Downs' planes. According to Natasha *et al.*, Tweed, as it considers the straight line at 90 degrees to the lower margin of the mandible, is independent of the anatomic variation of the chin and hence corresponds accurately with the gonial angle obtained on the OPG [19]. However, as per our study results Downs mandibular plane is the most reliable one, and we assume that since it uses the menton, i-e the lowest point on the chin, it is least affected by the anatomical differences, and most of the chin variations are usually depicted at the pogonion. The difference in our results compared to the Thilagarani study might also be because they stratified different types of malocclusion and had a larger sample size. In contrast to our findings, several studies reported a major disparity in the measurement of the gonial angle by lateral cephalometric and panoramic radiographs. Adil *et al.*, in their survey conducted in the hospital of 80 patients, outlined the gonial angle on radiographs (OPG and lateral Cephalogram) and found an important discrepancy in the measurement of the gonial angle between the two radiographs [15]. This may be because of the difference in malocclusions as our study incorporates all types of malocclusions, whereas only Class I malocclusion patients were included in Adil's study. Therefore, orthodontists should exercise caution when analyzing skeletal cephalometric variables from radiographs due to their lower predictability percentages. The difference in the outcomes from other studies could be due to the selection of various malocclusion types and the age of the patients. The differences in results could be due to our small sample size, and the precision and strength of our study would have been improved if this study had been conducted on a larger sample size [20].

This study had a relatively small sample size and included mixed malocclusion types, which may have influenced the variability and limited the generalizability of the findings. Additionally, inherent differences between radiographic techniques and potential measurement bias may have affected the accuracy of gonial angle assessment. Future studies with larger, stratified samples and standardized imaging protocols are recommended to validate the most

reliable method for gonial angle measurement.

CONCLUSIONS

It was concluded that the gonial angle serves as a crucial indicator for assessing facial growth patterns in patients. Both lateral cephalometric and panoramic X-rays are reliable methods for quantifying the gonial angle in orthodontic patients. The lateral cephalogram showed the mean value of the gonial angle as $123.06 \pm 6.80^\circ$, $121.5 \pm 6.40^\circ$, and $123.77 \pm 6.43^\circ$ using Tweeds, Steiner's, and Downs mandibular planes, respectively, while on OPG, the mean Gonial angle was 123.45 ± 6.89 . As per our study, Down's mandibular plane provides the value of the Gonial angle that is closest to that found on OPG.

Authors' Contribution

Conceptualization: MM

Methodology: MM, AS, AAS

Formal analysis: MM, AS, AAS

Writing and Drafting: MM, AS

Review and Editing: MM, AS, AAS

All authors approved the final manuscript and take responsibility for the integrity of the work

Conflicts of Interest

All the authors declare no conflict of interest.

Source of Funding

The author received no financial support for the research, authorship and/or publication of this article.

REFERENCES

- [1] Memon S, Agha D. Comparison Between Three Methods of Gonial Angle Formation on Lateral Cephalogram and Orthopantomogram. *Journal of the Pakistan Dental Association*. 2018Apr;27(2).doi:10.25301/JPDA.272.57.
- [2] Tashkandi NE, Alnaqa NH, Al-Saif NM, Allam E. Accuracy of Gonial Angle Measurements Using Panoramic Imaging Versus Lateral Cephalograms in Adults with Different Mandibular Divergence Patterns. *Journal of Multidisciplinary Healthcare*. 2024Dec: 1923-9. doi: 10.2147/JMDH.S463688.
- [3] Hasni M, Mengal N, Masooma B, Zehri M, Butt M, Nizam F *et al.* Reliability of Orthopantomogram in Determination of Gonial Angle. *Journal of Health and Rehabilitation Research*. 2024Mar;4(1):1-5.doi:10.61919/jhrr.v4i1.1738.
- [4] Baig MN. Reliability of Panoramic Radiography in Assessing the Gonial Angle Compared to the Lateral Cephalogram. *Pakistan Oral and Dental Journal*. 2018 Nov;38(3): 320-3.
- [5] Ganeiber T and Bugaighis I. Assessment of the Validity of Orthopantomographs in the Evaluation of Mandibular Steepness in Libya. *Journal of Orthodontic Science*. 2018Jan;7(1): 14.doi: 10.4103/jos.JOS_148_17.

- [6] Khan M, Akhtar FN, Jan A, Hamid F, Tariq S. Gonial Angle Determination; A Comparison Between Lateral Cephalogram and Both Hemispheres of Orthopantomogram. *Pakistan Armed Forces Medical Journal*. 2021 Aug; 71(4).
- [7] Khalid A abd Awaisi ZH. Linear and Angular Mandibular Measurements: Comparison Between Panoramic Radiography (Orthopantomogram) and Lateral Cephalogram: Linear and Angular Mandibular Measurements. *Pakistan Journal of Health Sciences*. 2023 May; 96-9. doi: 10.54393/pjhs.v4i05.740.
- [8] Girdhar A, Keerthika R, Narwal A, Kamboj M, Devi A, Sharma R. Comparative Manual and Digital Analysis of Gonial Angle in Lateral Cephalograms for Gender Determination. *Forensic Science, Medicine and Pathology*. 2024 Mar; 20(1): 73-8. doi: 10.1007/s12024-023-00625-2.
- [9] Jena S, Kabi D, Chaudhary G, Chaudhry A. Evaluation of Reliability and Validity of Linear and Angular Parameters via Analog and Digital Methods: A Lateral Cephalometric Analysis. *Iranian Journal of Orthodontics*. 2022 Dec; 17(2): 1-9. doi: 10.22034/ijo.2022.552416.1062.
- [10] Uslu-Akçam Ö. Gonial Angle Measurement: Panoramic Radiography or Lateral Cephalogram. *Essentials of Dentistry*. 2024 Mar; 3(1): 8-14. doi: 10.5152/EssentDent.2024.23033.
- [11] Bajracharya M, Rajbhandari A, Pradhan R, Manandhar P, Maharjan S, Pant BD. Gonial Angle by Lateral Cephalogram in Orthodontic Patients of a Tertiary Care Hospital: A Descriptive Cross-Sectional Study. *Journal of the Nepal Medical Association*. 2021 May; 59(237): 482. doi: 10.31729/jnma.6482.
- [12] Manohar MK. Establishing Cephalometric Norms for the Indian Population Using Steiner's Cephalometric Analysis. 2024.
- [13] Chatzigianni A. Cephalometric Radiography. In *Atlas of Dentomaxillofacial Anatomical Imaging*. Cham: Springer International Publishing. 2022 Jul: 59-72. doi: 10.1007/978-3-030-96840-3_6.
- [14] Sikaria S, Arthanari A, Ramalingam K, Ravindran V, Prathap L. Gonial Angle in Forensic Anthropology to Determine Age and Gender: A Population-Specific Analysis. *Cureus*. 2024 Jun; 16(6). doi: 10.7759/cureus.63481.
- [15] Adil S, Awan MH, Khan I, Syed K. Comparison of the Gonial Angle Measurements on Lateral Cephalogram and Both Hemispheres of Orthopantomogram. *Pakistan Orthodontic Journal*. 2015; 7(2): 48-50.
- [16] Hardin AM, Valiathan M, Oh H, Knigge RP, McNulty KP, Leary EV, Duren DL, Sherwood RJ. Clinical Implications of Age-Related Change of the Mandibular Plane Angle. *Orthodontics and Craniofacial Research*. 2020 Feb; 23(1): 50-8. doi: 10.1111/ocr.12342.
- [17] Bhullar MK, Uppal AS, Kochhar GK, Chachra S, Kochhar AS. Comparison of Gonial Angle Determination from Cephalograms and Orthopantomograms. *Indian Journal of Dentistry*. 2014 Jul; 5(3): 123. doi: 10.4103/0975-962X.140820.
- [18] Radhakrishnan PD, Varma NK, Ajith VV. Dilemma of Gonial Angle Measurement: Panoramic Radiograph or Lateral Cephalogram. *Imaging Science in Dentistry*. 2017 Jun; 47(2): 93. doi: 10.5624/isd.2017.47.2.93.
- [19] Natasha MM, Yuvapriya P, Jeyameera RR, Nandha M, Sukanya R. Exploring the Reliability and Accuracy of Gonial Angle Beyond Traditional Methods. *Journal of Advanced Medical and Dental Sciences Research*. 2024 Nov; 12(11): 21-6.
- [20] Rajak RR, Shrestha RM, Koju S. Reliability of Panoramic Radiography in Assessing Gonial Angle Compared to Lateral Cephalogram in Patients with Class I Malocclusion. *Taiwanese Journal of Orthodontics*. 2021; 33(2): 2. doi: 10.38209/2708-2636.1096.