



Original Article



Presoaking of Peroneus Longus Tendon Auto-graft in Vancomycin Decreases the Occurrence of Infection Following Arthroscopic Primary Anterior Cruciate Ligament Reconstruction

Abdul Munaf Saud¹, Muhammad Rashid², Tauseef Raza³, Abdul Rasheed Napar⁴, Naveed Khan⁵ and Syed Abdur Rub Abidi⁵

¹Department of Orthopedic Surgery, Bahawal Victoria Hospital, Bahawalpur, Pakistan

²Department of Orthopedic Surgery, Sahiwal Medical College, Teaching Hospital, Sahiwal, Pakistan

³Department of Orthopedic Surgery, Khyber Medical University Institute of Medical College, Peshawar, Pakistan

⁴Department of Orthopedic Surgery, Khairpur Medical College, Khairpur Mir, Pakistan

⁵Department of Orthopedic Surgery, Jinnah Medical and Dental College, Karachi, Pakistan

ARTICLE INFO

Keywords:

Vancomycin, Presoaking, Anterior Cruciate Ligament, Septic Arthritis

How to Cite:

Saud, A. M., Rashid, M., Raza, T., Napar, A. R., Khan, N., & Abidi, S. A. R. (2025). Presoaking of Peroneus Longus Tendon Auto-graft in Vancomycin Decreases the Occurrence of Infection Following Arthroscopic Primary Anterior Cruciate Ligament Reconstruction: Presoaking of Peroneus Longus Tendon Auto-graft in Vancomycin. *Pakistan Journal of Health Sciences*, 6(4), 243-247. <https://doi.org/10.54393/pjhs.v6i4.2959>

***Corresponding Author:**

Abdul Munaf Saud
Department of Orthopedic Surgery, Bahawal Victoria Hospital, Bahawalpur, Pakistan
drabdulmunafsaud@gmail.com

Received date: 7th March, 2025

Revised date: 23rd April, 2025

Acceptance date: 25th April, 2025

Published date: 30th April, 2025

ABSTRACT

Septic arthritis following anterior cruciate ligament (ACL) repair surgery is an extremely rare but possibly fatal consequence. To mitigate this danger, our team began presoaking grafts with vancomycin. **Objectives:** To determine the association of septic arthritis following anterior cruciate ligament (ACL) restoration using hamstring autografts with and without grafts presoaked in vancomycin. **Methods:** This study included 350 patients who had primary hamstring autograft ACL repair. Patients were equally divided into two groups. Group I had a pre-vancomycin protocol among 175 cases, and 175 cases of Group II received the vancomycin protocol. Postoperative septic arthritis was a likely outcome in both groups. Combining clinical findings with cytological examination of joint aspiration (cell count >50,000/ μ L and >90% neutrophils), a diagnosis of likely septic arthritis was reached. A Fisher's exact test was used for statistical analysis. We fixed the significance level at $p < 0.05$. **Results:** There were a majority of 240 (68.6%) male and 110 (31.4%) female among all cases. Included cases had a mean age of 27.18 ± 11.58 years and had a mean BMI of 26.12 ± 8.38 kg/m². Post-operatively, the frequency of septic arthritis was only found in group I among 7 (17.1%) cases, and no cases were found in group II. Among 7 cases of septic arthritis in group I, 4 cases had *Staphylococcus epidermidis*, and no organisms were isolated in 3 cases. **Conclusions:** It was concluded that presoaking the grafts in vancomycin for primary ACL repair decreased the likelihood of postoperative septic arthritis compared to not soaking them.

INTRODUCTION

A very uncommon but disastrous complication of anterior cruciate ligament (ACL) surgery is knee septic arthritis, the incidence of which has been reported in the literature to range from 0.14% to 1.07% [1]. Even with the most advanced treatment, complications like as graft failure, deterioration of articular cartilage, and long-term joint dysfunction can occur [2]. Infection is more likely to occur with hamstring autograft than with patellar tendon,

quadriceps tendon, or allograft when used after ACL replacement [3]. Most people think it's because of contamination that happened during the graft's collection and processing, but no one knows for sure [4]. To address the potential risk of postoperative septic arthritis caused by a graft that is contaminated, Vertullo et al., developed the Vancomycin presoaking approach in 2012 [4]. Improving the antibiotic's efficacy in a specific graft was



their primary objective. During the arthroscopic part of the surgery, the surgeon will often use a swab saturated with a 5 mg/mL Vancomycin solution to wrap the prepared graft. Due to its favourable pharmacokinetic characteristics, vancomycin is an excellent agent. Some of these characteristics include a large distribution volume, low allergenicity, heat stability, and local applicability [5]. Staphylococcus aureus and coagulase-negative staphylococci are among the most common skin commensals that might cause infections following ACL repairs. It eliminates these bacteria, to put it [6]. The goal of the study reported by Pérez-Prieto et al., was to identify the exact moment in the graft collection and preparation process when contamination can occur [7]. Because of this, graft samples were collected both during processing and harvesting. Of the total, seven cases (or 14%) were determined to have graft contamination. Two instances (4% of the total) occurred during harvesting, while five (10%) occurred during graft preparation. In 2012, Vertullo et al., [4] suggested the "vancomycin wrap" approach to enhance the antibacterial efficacy of the graft in response to the concern that a contaminated graft could lead to postoperative septic arthritis [7]. One step of the procedure is to place the ACL graft in a sterile bag or tray, swab it, and then dip the swab into a vancomycin solution. The infection rate decreased from 1.4% to 0% after ACL replacement, according to the initial study. Multiple subsequent studies using identical methodology corroborated the results of Vertullo and colleagues [8, 9]. Vancomycin is a great agent because of its pharmacokinetic properties. A few examples include its low allergenicity, heat stability, and local use safety, as well as its large distribution volume. It eliminates skin commensals, which make up the vast majority of microorganisms that cause infections during ACL repair. This includes coagulase-negative staphylococci and Staphylococcus aureus [10]. The antibiotic vancomycin is highly efficient against Gram-positive cocci because it prevents the development of the bacterial cell wall. Staphylococcus aureus, Streptococcus pyogenes, Streptococcus pneumoniae, and other similar bacteria are particularly susceptible to the long-term effects of this antibiotic. Orthopedic surgeons often prescribe vancomycin to patients suffering from septic arthritis and related conditions. Topical vancomycin has demonstrated encouraging results in non-orthopedic domains as well, with the most encouraging results in orthopedic spine surgery [11]. A prior randomized research found that surgical site infection (SSI) was less common when patients received preventative intrawound injections of vancomycin after fracture stabilization surgery [11, 12]. Initial suggestions that tendon grafts saturated with vancomycin could significantly reduce postoperative

infection risks were made in 2012 by Vertullo et al., [4]. Studying how well this method (hamstring grafts soaked in vancomycin) reduced the occurrence of septic arthritis compared to the period before it was employed was the main goal of this investigation. We hypothesized that compared to the control group, those who received grafts presoaked with vancomycin would have a lower incidence of septic arthritis.

Septic arthritis following primary anterior cruciate ligament (ACL) reconstruction is a rare but serious complication that can lead to graft failure, joint damage, and poor long-term knee function. Although vancomycin presoaking of grafts has shown promising infection-prevention benefits internationally, limited regional evidence exists regarding its effectiveness specifically with peroneus longus tendon autografts in local orthopedic practice. This study aims to determine the association of septic arthritis following anterior cruciate ligament (ACL) restoration using hamstring auto grafts with and without grafts presoaked in vancomycin.

METHODS

In this quasi-experimental study, 350 patients who underwent arthroscopic primary ACL reconstruction with a hamstring autograft were included. The demographics of the enrolled cases were documented in detail following the acquisition of informed written consent. The study was conducted in Sahiwal Medical College /Sahiwal Teaching Hospital, and the approved IRB reference number was 157/IRB/SLMC/SWL. Study duration was 8 months, May-Dec 2024. The sample size is calculated by keeping the power of the study equal to 80% and the level of significance equal to 5%. With 10% expected dropout, the sample of subjects by infection with vancomycin presoaked grafts was 0.09% and without vancomycin presoaked grafts infection rate as 2.4% [13]. Included patients were aged between 18-55 years. Patients who had hamstring autografts, ACL reconstructions, multiple ligament surgeries, bilateral surgeries, or open concurrent operations were not eligible. We divided the patients into two groups. Group I had a pre-vancomycin protocol among 175 cases, and 175 cases of Group II received the vancomycin protocol. An ACL Tight Rope (Arthrex) cortical button and a Bio Composite interference screw (Arthrex) were used in the femoral and tibial sides of the hamstring autograft ACL reconstruction, respectively, in the surgical procedure. A 5-strand technique was used for hamstring graft preparation when the graft was thinner than 8 mm, following previous publications by our group [3]. A normal 4-strand technique was employed when the graft was thicker than 8 mm. A 5-strand hamstring graft was administered to 130 patients of group I and 150 patients of group II, who received a 4-strand graft. During the surgical procedure, a Bio-Composite interference screw (Arthrex) and an ACL Tight Rope (Arthrex) cortical button were

utilized on the tibial and femoral sides of the hamstring autograft ACL repair, respectively. Hamstring grafts were prepared according to our group's previous publications³: a 5-strand method was used for grafts thinner than 8 mm, and a conventional 4-strand procedure was utilized for grafts thicker than 8 mm. For starters, the graft had to be worked more than the standard four-strand double semitendinosus and gracilis graft. In the time leading up to surgery, all patients were administered intravenous antibiotics, specifically vancomycin. All patients were administered intravenous antibiotics before the procedure, and the graft was soaked in a vancomycin solution beforehand, as per the technique outlined by Vertullo et al., [4]. Before surgery, patients were given either a 2-g dosage of intravenous cefazolin or a 1-g dose of intravenous vancomycin, depending on whether a penicillin allergy was noted. This was done to minimize antibiotic-related problems. A surgical sponge was saturated with a 5-mg/mL vancomycin solution before the hamstring transplant was prepared to ensure it would be properly soaked. A surgical sponge is preferable to immersing the graft in the solution, which might cause it to lose some of its original diameter as a result of fluid absorption. A 100 mL sterile saline solution containing 500 mg of vancomycin powder was prepared. As part of the arthroscopic procedure for the reconstruction, the graft had to be wrapped for at least 15 minutes [14]. Probable septic arthritis was diagnosed based on the patient's symptoms, which included redness, swelling, decreased range of motion, localized heat, and/or swelling of the knee. After every occurrence where suspicion was detected by arthrocentesis, the synovial fluid sample was tested cytologically and cultured. When the cell count exceeded 50,000/ μ L, the neutrophil count was above 90%, and a positive culture was also detected, a diagnosis of septic arthritis was deemed highly likely [15]. Septic arthritis could only be detected within 30 days, therefore, it was decided that a minimum follow-up of 5 months was necessary. The operating surgeon oversaw all of the subsequent appointments. SPSS 22.0 was used for analysis. All the qualitative variables, like gender, marital status, post-operative outcomes and functionality outcomes, were analyzed by frequency and percentages. All the quantitative variables, like age and BMI, were presented by Mean \pm SD. When comparing the two categories "septic arthritis" and "no septic arthritis," the Fisher exact test or chi-square test was used for analysis. The threshold of significance utilized was $p < 0.05$.

RESULTS

There were a majority of 240 (68.6%) male and 110 (31.4%) female among all cases. Included cases had a mean age 27.18 \pm 11.58 years and had a mean BMI of 26.12 \pm 8.38 kg/m². 195 (55.7%) cases were married (Table 1).

Table 1: Demographics of the Presented Cases (n=82)

Variables	n (%)
Gender	
Male	240 (68.6%)
Female	110 (31.4%)
Mean Age (Years)	27.18 \pm 11.58
Mean BMI (kg/m ²)	26.12 \pm 8.38
Marital Status	
Yes	195 (55.7%)
No	155 (44.3%)

Post-operatively, the frequency of septic arthritis was only found in group I among 7 (17.1%) cases and no cases were found in group II (Table 2).

Table 2: Post-Operative Comparison of Outcomes Among Both Groups

Variables	Group I (175)	Group II (175)	p-Value
Good			
Yes	7 (17.1%)	0	<0.005
No	168 (82.9%)	175 (100%)	

Among 7 cases of septic arthritis in group I, 4 cases had Staphylococcus epidermidis, and no organisms were isolated in 3 cases (Figure 1).

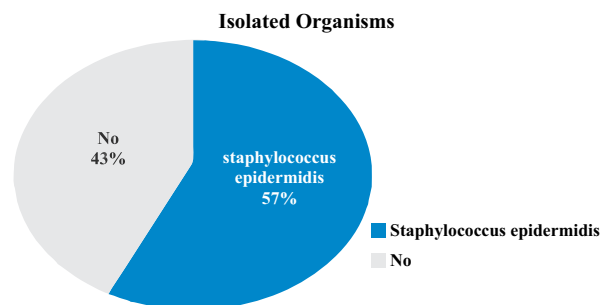


Figure 1: Frequency of Isolated Organisms Among Septic Arthritis Infection was found in 8 (4.6%) cases of Group I, and there was no infection found among cases of Group II, with a p-value < 0.005 (Table 3).

Table 3: Post-Treatment Comparison of Infection Among Both Groups

Variables	Group I (175)	Group II (175)	p-Value
Infection			
Yes	8 (4.6%)	0	<0.005
No	167 (95.4%)	175 (100%)	

After 1 year of follow-up, better knee functionality was observed among patients of the vancomycin group as compared to group I, with a p-value < 0.002 (Table 4).

Table 4: Comparison of Functionality Outcomes

Variables	Group I (175)	Group II (175)	p-Value
Functionality Outcomes			
Good	157 (89.7%)	173 (98.9%)	<0.002
Poor	18 (10.3%)	2 (1.1%)	

DISCUSSION

Current findings corroborated those of other research that found no infection when using hamstring grafts presoaked with vancomycin for ACL restoration [13, 15]. Before implementing this procedure, the infection rate was 1.7%, which is at the upper end of the indicated ranges. However, no infections were detected when this approach was used. In comparison to our earlier research, this increase in infection incidence may be explained by the longer manipulation time needed to construct a 5-strand graft as opposed to a typical double semitendinosus and gracilis graft. Pérez-Prieto et al., found that the preparation phase was the most common time for graft contamination [7]. Thankfully, their research demonstrated that not a single graft sample showed bacterial growth while immersed in vancomycin solution. A follow-up research of the original findings was published by the same group that published the first study on the topic, but with additional patients and a longer follow-up period [16]. In a study that followed 1,585 patients for 13 years after ACL restoration using a hamstring autograft, the researchers found no cases of infection. In their study, Offerhaus et al., found that deep knee infections occurred 2% of the time after surgery in patients who did not get grafts presoaked in vancomycin, but did not occur 0% in those patients who did [13]. Their results also demonstrated that vancomycin did not increase the risk of arthrofibrosis, negative clinical ratings, or graft failure. A biomechanical model in pig tendons was published by Schüttler et al., to assess the safety of using vancomycin in graft tendons. Their investigation revealed no evidence of biomechanical damage to tendons following the use of vancomycin wraps [18].

This study's creative application of 5-strand grafts sets it apart from others on the subject. New strategies for dealing with a small hamstring autograft diameter could lengthen the time required to prepare and handle the graft, increasing the risk of joint infection [19]. This series' total eradication of septic arthritis demonstrates that a safe hamstring transplant preparation technique must include vancomycin presoaking. The biomechanical characteristics of human semitendinosus transplants from living donors were found to be unaltered by presoaking with 5 mg/mL of vancomycin at time zero by Jacquet et al., [20]. Return to running and overall knee function were not different between the control group and the patients given Vancomycin, according to Figueroa et al., and Bohu et al., respectively [21, 22]. Comparing the study's graft failure rate to the control group, which did not receive Vancomycin, revealed no rise in postoperative arthro-fibrosis or subjective outcome scores. However, the long-term biomechanical effects of its use have not been studied. Also, compared with the control group,

patients who received grafts soaked in Vancomycin were more likely to resume their pre-injury sport.

CONCLUSIONS

It was concluded that presoaking the grafts in vancomycin for primary ACL repair decreased the likelihood of postoperative septic arthritis compared to not soaking them.

Authors' Contribution

Conceptualization: NK

Methodology: MR, TR

Formal analysis: AMS

Writing and Drafting: AMS, TR, ARN, SARA

Review and Editing: AMS, TR, ARN, SARA, NK, MR

All authors approved the final manuscript and take responsibility for the integrity of the work

Conflicts of Interest

All the authors declare no conflict of interest.

Source of Funding

The author received no financial support for the research, authorship and/or publication of this article.

REFERENCES

- [1] Viola R, Marzano N, Vianello R. An Unusual Epidemic of Staphylococcus-Negative Infections Involving Anterior Cruciate Ligament Reconstruction with Salvage of the Graft and Function. *Arthroscopy: The Journal of Arthroscopic and Related Surgery*. 2000 Mar; 16(2): 173-7. doi: 10.1016/S0749-8063(00)90032-
- [2] X.Fong SY and Tan JL. Septic Arthritis After Arthroscopic Anterior Cruciate Ligament Reconstruction. *Annals-Academy of Medicine Singapore*. 2004 Mar; 33(2): 228-34. doi: 10.47102/annals-acadmedsg.V33N2p228.
- [3] Monaco E, Maestri B, Labianca L, Speranza A, Vadalà A, Iorio R et al. Clinical and Radiological Outcomes of Postoperative Septic Arthritis After Anterior Cruciate Ligament Reconstruction. *Journal of Orthopedic Science*. 2010 Mar; 15: 198-203. doi: 10.1007/s00776-009-1447-3.
- [4] Vertullo CJ, Quick M, Jones A, Grayson JE. A Surgical Technique Using Presoaked Vancomycin Hamstring Grafts to Decrease the Risk of Infection After Anterior Cruciate Ligament Reconstruction. *Arthroscopy: The Journal of Arthroscopic and Related Surgery*. 2012 Mar; 28(3): 337-42. doi: 10.1016/j.arthro.2011.08.301.
- [5] Jefferies JG, Aithie JM, Spencer SJ. Vancomycin-Soaked Wrapping of Harvested Hamstring Tendons During Anterior Cruciate Ligament Reconstruction. A Review of the 'Vancomycin Wrap'. *The Knee*. 2019 Jun; 26(3): 524-9. doi: 10.1016/j.knee.2019.04.008.
- [6] Dhammi IK, Haq RU, Kumar S. Prophylactic Antibiotics in Orthopedic Surgery: Controversial Issues in Its Use. *Indian Journal of Orthopedics*. 2015 Jul; 49(4): 373.

- doi:10.4103/0019-5413.159556.
- [7] Pérez-Prieto D, Portillo ME, Torres-Claramunt R, Pelfort X, Hinarejos P, Monllau JC. Contamination Occurs During ACL Graft Harvesting and Manipulation, But It Can Be Easily Eradicated. *Knee Surgery, Sports Traumatology, Arthroscopy*. 2018 Feb; 26: 558-62. doi: 10.1007/s00167-017-4735-z.
- [8] Kim EK, Donnelley CA, Tiew M, Roberts HJ, Von Kaeppler E, Shearer D et al. Prophylactic Topical Antibiotics in Fracture Repair and Spinal Fusion. *Advances in Orthopedics*. 2021; 2021(1): 1949877. doi: 10.1155/2021/1949877.
- [9] AlShareef HM. Anterior Cruciate Ligament (ACL) Reconstruction Using Hamstring Autografts Infused in vancomycin Lowers the Risk of Infection Following Surgery Without Impairing Knee Function: A Retrospective Study. *EC Orthopaedics*. 2024; 15: 01-7.
- [10] Baron JE, Shamrock AG, Cates WT, Cates RA, An Q, Wolf BR et al. Graft preparation with intraoperative vancomycin decreases infection after ACL reconstruction: a review of 1,640 cases. *The Journal of Bone and Joint Surgery*. 2019 Dec; 101(24): 2187-93. doi: 10.2106/JBJS.19.00270.
- [11] Negrin LL, Zeitler C, Hofbauer M. Patellar Size Variation at the Quadriceps Tendon-Bone Block Harvest Site: A Magnetic Resonance Imaging Study to Evaluate the Safe Zone for Harvesting a Sufficient Bone Block. *The American Journal of Sports Medicine*. 2021 Dec; 49(14): 3850-8. doi: 10.1177/03635465211049226.
- [12] Park JY, Fernandes A, Park SY, Lim H, Sayudo IF, Leibovitch L et al. Comparative Effectiveness of Peroneus Longus Tendon (PLT) Autografts Versus Hamstring Tendon (HT) Auto grafts in Anterior Cruciate Ligament Reconstruction: A Comprehensive Systematic Review and Meta-Analysis. *European Journal of Orthopedic Surgery and Traumatology*. 2024 Jul; 34(5): 2691-9. doi: 10.1007/s00590-024-03984-w.
- [13] Offerhaus C, Balke M, Hente J, Gehling M, Blendl S, Höher J. Vancomycin Pre-Soaking of the Graft Reduces Postoperative Infection Rate without Increasing Risk of Graft Failure and Arthrofibrosis in ACL Reconstruction. *Knee Surgery, Sports Traumatology, Arthroscopy*. 2019 Sep; 27: 3014-21. doi: 10.1007/s00167-018-5323-6.
- [14] Figueroa D, Figueroa F, Calvo R, Lopez M, Goñi I. Presoaking of Hamstring Autografts in Vancomycin Decreases the Occurrence of Infection Following Primary Anterior Cruciate Ligament Reconstruction. *Orthopedic Journal of Sports Medicine*. 2019 Sep; 7(9): 2325967119871038. doi: 10.1177/2325967119871038.
- [15] Charalambous CP, Ahmed EM, Kayali F, Nautiyal H, Kuršumović K, Sutton PM. Vancomycin Graft Presoaking in Anterior Cruciate Ligament Reconstruction Surgery Is Associated with a Lower Risk of Graft Re-rupture as Compared with No Vancomycin Presoaking: Systematic Review and Meta-analysis. *The Journal of Bone and Joint Surgery Reviews*. 2023 Dec; 11(12): e23. doi: 10.2106/JBJS.RVW.23.00145.
- [16] Phegan M, Grayson JE, Vertullo CJ. No Infections in 1300 Anterior Cruciate Ligament Reconstructions with Vancomycin Pre-Soaking of Hamstring Grafts. *Knee Surgery, Sports Traumatology, Arthroscopy*. 2016 Sep; 24: 2729-35. doi: 10.1007/s00167-015-3558-z.
- [17] Naendrup JH, Marche B, de SA D, Koenen P, Otchwemah R, Wafaisade A et al. Vancomycin-Soaking of the Graft Reduces the Incidence of Septic Arthritis Following ACL Reconstruction: Results of A Systematic Review and Meta-Analysis. *Knee Surgery, Sports Traumatology, Arthroscopy*. 2020 Apr; 28: 1005-13. doi: 10.1007/s00167-019-05353-1.
- [18] Schüttler KF, Scharm A, Stein T, Heyse TJ, Lohoff M, Sommer F et al. Biomechanical and Microbiological Effects of Local Vancomycin in Anterior Cruciate Ligament (ACL) Reconstruction: A Porcine Tendon Model. *Archives of Orthopedic and Trauma Surgery*. 2019 Jan 22; 139: 73-8. doi: 10.1007/s00402-018-3006-x.
- [19] Fritsch B, Figueroa F, Semay B. Graft Preparation Technique to Optimize Hamstring Graft Diameter for Anterior Cruciate Ligament Reconstruction. *Arthroscopy Techniques*. 2017 Dec; 6(6): e2169-75. doi: 10.1016/j.eats.2017.08.011.
- [20] Jacquet C, Jaubert M, Pioger C, Sbihi A, Pithioux M, Le Baron M et al. Presoaking of Semitendinosus Graft with Vancomycin Does Not Alter Its Biomechanical Properties: A Biomechanical in Vitro-Controlled Study Using Graft From Living Donors. *Arthroscopy: The Journal of Arthroscopic and Related Surgery*. 2020 Aug; 36(8): 2231-6. doi: 10.1016/j.arthro.2020.03.037.
- [21] Figueroa F, Figueroa D, Calvo R, Vaisman A, Nuñez M, Putnis S. Vancomycin Presoaking of the Graft Appears to Prevent Infection After Anterior Cruciate Ligament Reconstruction: A Systematic Review and Meta-Analysis. *Journal of Hospital for Special Surgery*. 2022 Feb; 18(1): 138-44. doi: 10.1177/15563316211011682.
- [22] Bohu Y, Klouche S, Sezer HB, Herman S, Grimaud O, Gerometta A et al. Vancomycin-Soaked Auto Grafts During ACL Reconstruction Reduce the Risk of Post-Operative Infection without Affecting Return to Sport or Knee Function. *Knee Surgery, Sports Traumatology, Arthroscopy*. 2020 Aug; 28: 2578-85. doi: 10.1007/s00167-020-05879-9.