DOI: https://doi.org/10.54393/pjhs.v6i2.2693

PAKISTAN JOURNAL OF HEALTH SCIENCES
(LAHORE)
https://thejas.com.pk/index.php/pjhs
ISSN (E): 2790-9352, (P): 2790-9344
Volume 6, Issue 02 (February 2025)

Case Study

# A Rare Case of Metachromatic Leukodystrophy (MLD)

**Ikhlaq Ahmad[1], Bilal Khan[2], Saeed Khan[3], Hamdah Bashir Mughal[4], Abdul Quddus[5] and Aiman Naveed[5*]**

[1]Department of Public Health, Health Services Academy, Islamabad, Pakistan
[2]Department of General Medicine, Quaid-e-Azam International Hospital, Islamabad, Pakistan
[3]Department of General Medicine, Saidu Group of Teaching Hospital, Saidu Sharif, Pakistan
[4]Department of Biochemistry, Azad Jammu And Kashmir Medical College Azad, Kashmir, Pakistan
[5]Inspection Department, Islamabad Healthcare Regulatory Authority, Islamabad, Pakistan

## ARTICLE INFO

***Keywords:***
Autosomal Recessive, Genetic Screening, Arylsulfatase A, Metachromatic Leukodystrophy, Neuroimaging, Consanguinity

***How to Cite:***
Naveed, A., Ahmad, I., Khan, B., Khan, S., Mughal, H. B., & Quddus, A. (2025). A Rare Case of Metachromatic Leukodystrophy (MLD): Case of Metachromatic Leukodystrophy. Pakistan Journal of Health Sciences, 6(2), 263-267. https://doi.org/10.54393/ pjhs.v6i2.2693

***Corresponding Author:***
Aiman Naveed
Inspection Department, Islamabad Healthcare Regulatory Authority, Islamabad, Pakistan
aimannaveed3232@gmail.com

Received date: 17th December, 2024
Acceptance date: 16th February, 2025
Published date: 28th February, 2025

## ABSTRACT

Metachromatic Leukodystrophy (MLD) is a rare hereditary lysosomal storage disorder affecting white matter, often leading to progressive motor and cognitive decline. This case presents a 30-month-old child from a consanguineous family who was in good health four months prior but initially exhibited mild symptoms of diarrhea and a chest infection before rapidly deteriorating neurologically. The delayed diagnosis highlights the challenges of early recognition in resource-limited settings. MRI findings, coupled with genetic testing, confirmed the diagnosis, emphasizing the importance of integrating neuroimaging with molecular diagnostics. This case underscores the critical need for prenatal and newborn genetic screening, particularly in populations with a high prevalence of consanguinity, to facilitate timely interventions and improve disease management. Early recognition and a multidisciplinary approach, including genetic counseling, can enhance outcomes and inform future preventive strategies for at-risk families.

## INTRODUCTION

Metachromatic leukodystrophy (MLD) is an unusual medical condition that results in the decline of myelin owing to the genetic alterations in the arylsulfatase A (ARSA) gene located on chromosome 22q13.33 [1]. Additionally, the PSAP (Prosaposin) gene plays a crucial role in sphingolipid metabolism by encoding saposin proteins, which are necessary for ARSA activation, further highlighting the genetic complexity of MLD pathogenesis in this case. Mutations in the ARSA gene, such as point mutations, deletions, and splice site alterations, can lead to reduced or absent arylsulfatase A enzyme activity, resulting in metachromatic leukodystrophy (MLD). Several mutations in the ARSA gene, such as c.465+1G>A and c.1283C>T, have been identified to cause severe phenotypic expressions of MLD. These mutations interfere with proper enzyme folding and activity, leading to a significant buildup of sulfatides. Additionally, genes like SUMF1 have been shown to modulate ARSA enzyme functionality, offering insights into the broader genetic mechanisms influencing disease progression [2]. In the central nervous system this conglomeration leads to continuous myelin damage [3]. MLD leads to demyelination, resulting in symptoms namely


Copyright © 2025. PJHS, Published by Crosslinks International Publishers LLC, USA
This work is licensed under a Creative Commons Attribution 4.0 International License.

**DOI:** https://doi.org/10.54393/pjhs.v6i2.2693

reduced motor function, spastic tetraparesis, ataxia, muscle spasms, optic atrophy, and cognitive decline [4]. Motor diminution is a primary attribute in metachromatic leukodystrophy (MLD) [5]. The global incidence of metachromatic leukodystrophy (MLD) is estimated to range from approximately 1 in 40,000 to 1 in 160,000 live births, with prevalence varying across different regions [6]. In Pakistan, the cultural tradition of consanguineous marriages contributes to a higher incidence of inherited metabolic disorders like MLD compared to other regions globally [7]. The precise prevalence of MLD in Pakistan remains unclear; however, research indicates a significant association between consanguinity and genetic disorders, underscoring the importance of genetic counseling and screening in managing these conditions [8].

This case study of a thirty months old boy explained the clinical manifestation, diagnostic issues, and management strategies.

**Case Presentation**

This was a case of a thirty months old boy of a consanguineous parent. The case was presented at Saidu Group of Teaching Hospital, Swat, Khyber Pakhtunkhwa, in the Pediatric/Neurology Department for detailed evaluation and management. His parents explained that he was living a normal life for first four months of his life. The child was admitted to the hospital with diarrhea and chest infection. During his stay in the hospital, the child also experienced regression of developmental milestones and myoclonic jerks. Initially, gross motor movement impacted. With time, the child was unable to sit and eventually, head control compromised. The child admitted to the pediatric neurology ward on basis of aforementioned complaints for further investigation. An Electroencephalogram (EEG) conducted on the patient showed a burst suppression pattern, which is a sign of abnormal brain activity. Additionally, the Magnetic Resonance Imaging (MRI) scan revealed abnormal signals in the cerebral periventricular and deep white matter, which were symmetric and confluent on both sides (Figure 1). Based on these findings, genetic testing was recommended, which revealed a homozygous variant in the ARSA gene. In addition to palliative care, the patient was encouraged to carry on with physiotherapy sessions to maintain as much mobility as possible. The physician informed the parents of the child that the prognosis suggests a continued decline, and existing treatments have proven unsatisfactory. The patient was observed from January 2022 to June 2022. The patient was under observation for three months, followed by a confirmed diagnosis of MLD. Over the next three months, the child's condition progressively worsened, leading to recurrent episodes of aspiration pneumonia. Ultimately, the child passed away due to complications arising from the disease.

**MRI and Genetic Analysis Findings**

There is confluent bilateral symmetrical homogenous intermediate high T2 and FLAIR abnormal signal in the cerebral periventricular and deep white matter predominantly in the frontal, parietal, and occipital lobes. Relatively faint T2/FLAIR high signal is also noted in the splenium of the corpus callosum which otherwise appears unremarkable. The subcortical white matter and basal ganglia including internal capsule are spared. Normal gray matter signal is demonstrated. No overt brain parenchymal hypertrophic or atrophic changes are seen. Bilateral cerebellopontine angles are grossly unremarkable. Orbits, optic nerves, and chiasm appear unremarkable. There is no evidence of acute intracranial hemorrhage or infarct. No intracranial space-occupying lesion or radiological signs of raised intracranial pressure are seen. There is no evidence of hydrocephalus. The basal cisterns are unremarkable. There is no radiological evidence of cortical migration anomalies or cortical dysplasia. Medial temporal morphology is also bilaterally grossly symmetrical and unremarkable. No gross cranial vault lesion is demonstrated. Metachromatic leukodystrophy (MLD) was confirmed to follow an autosomal recessive inheritance pattern in this case. Genetic analysis identified a homozygous pathogenic variant in the ARSA gene in the affected child. Both parents were initially advised to undergo genetic screening, which would have confirmed them as heterozygous carriers of the same ARSA mutation. However, they declined the screening. The consanguineous nature of the family likely contributed to the inheritance of this genetic disorder, highlighting how such familial connections can increase the risk of autosomal recessive diseases like MLD.

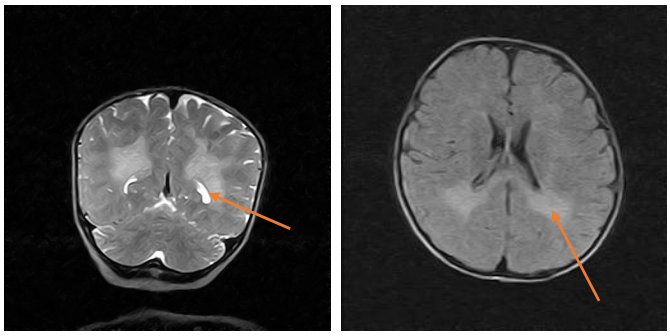

**Figure 1:** Arrows Showed Symmetrical Confluent Bilateral Abnormal Cerebral Periventricular White Matter

## DISCUSSION

Metachromatic Leukodystrophy (MLD) is an uncommon neural degeneration disorder owing to lack of an enzyme called arylsulfatase A. This case study highlighted several critical aspects of MLD that demand further exploration. Firstly, the clinical presentation of our patient harmonized


Copyright © 2025. PJHS, Published by Crosslinks International Publishers LLC, USA
This work is licensed under a Creative Commons Attribution 4.0 International License.

**DOI:** https://doi.org/10.54393/pjhs.v6i2.2693

with typical features of MLD that reinforced the importance of recognizing nuanced neurological symptoms early in the disease course. The consanguinity of the parents in this case served as a vital factor in the hereditary basis of MLD. This highlighted the importance of extra vigilance in clinical assessments, particularly in cases with a family history of consanguinity. This experience highlighted the call for a multidisciplinary strategy by integrating medical examination, neuroimaging studies, and genetic testing to achieve accurate and timely diagnosis. Other cases from the literature review are presented below. This case aligned typical MLD features, emphasized the importance of early recognition of neurological symptoms. The consanguinity of the parents was crucial in the hereditary basis of MLD, highlighted the need for extra vigilance in such families. This experience underscored the value of a multidisciplinary approach, combining medical examination, neuroimaging, and genetic testing for an accurate diagnosis. Patil SA and Maegawa GH studied 18 MLD patients similarly found a high incidence of consanguinity and abnormal electromyography, supported the importance of genetic assessment in MLD diagnosis [9]. The MRI findings in this case, showed bilateral symmetrical T2 and FLAIR hyperintensities in the periventricular and deep white matter with sparing of subcortical U-fibers, aligned with those reported in the study of an adult Chinese MLD patient with ARSA mutations. Both cases highlighted the characteristics white matter changes in MLD, though our case also notes involvement of the splenium of the corpus callosum [10]. These findings reinforced the importance of genetic analysis in diagnosing MLD and the need for counseling in consanguineous families. The MRI findings demonstrated symmetrical periventricular and deep white matter hyperintensities on T2 and FLAIR imaging, align with the patterns used in the "Metachromatic Leukodystrophy: A Scoring System for Brain MR Imaging Severity" study to assess disease severity [11]. While this case did not employ a formal scoring system, the characteristic distribution of white matter changes highlighted the utility of MRI in evaluating and potentially monitoring disease progression. Incorporating such scoring systems could enhance the objective assessment and tracking of MLD in future cases. A study conducted by Kubaski *et al.*, investigated the quantification of sulfatides levels in the amniotic fluid supernatant. This study highlighted the significance of timely assessment for detecting MLD. This study proved that sulfatide quantification in amniotic fluid can facilitate in a rapid and correct identification of MLD patients [12]. Rastogi *et al.*, emphasized the critical role of MRI in diagnosing MLD, highlighting classical features such as gait and psychiatric disturbances alongside characteristic brain MRI findings, including the tigroid pattern. The case aligned with these clinical features and underscored the importance of MRI in identifying the characteristic white matter changes associated with MLD [13]. Kehrer *et al.*, describe the intrinsic pathway of gross motor regression in late-stage infantile MLD, noting that all patients exhibit severe impairment of gross motor coordination. This aligned with this case study findings, as the patient in this case also experienced a complete loss of gross motor functions, highlighted the progressive nature of motor deterioration in MLD and its impact on quality of life [5]. There are no approved treatments for MLD; however, Shaimardanova *et al.*, discussed in diagnosis, modeling and treatment approached for MLD that the majority of patients treated with symptomatic therapies, included antiepileptic drugs for seizures, muscle relaxants, physiotherapy, and anti-inflammatory treatments like prednisolone or IVIg. Symptomatic treatment given in this case to the patient [4]. While these treatments provide symptom relief, they do not address the underlying cause or pathogenesis of the disease and have no impact on the progression rate. Gene therapy and integrated gene and cell interventions are emerging as promising approaches for treating MLD. Biffi *et al.*, in 2008 highlighted the limitations of HSCT in MLD treatment and discussed emerging gene therapy approaches using autologous hematopoietic stem/progenitor cells to enhance arylsulfatase-A expression, potentially overcoming HSCT-related challenges [14]. Mallikarjun *et al.*, in 2011 presented a rare case of Metachromatic Leukodystrophy (MLD), emphasizing its clinical variability and diagnostic challenges [15]. This aligned with Politi *et al.*, in 2018, who highlighted the frequent misdiagnosis of MLD, underlining the need for improved diagnostic accuracy [16]. In support of this, Borges *et al.*, in 2020 discussed the difficulties in early pediatric diagnosis, which is crucial for timely intervention [17]. Fumagalli *et al.*, in 2021 provided a longitudinal perspective on 45 patients, offering insights into disease progression and treatment outcomes [18]. Gieselmann and Krägeloh-Mann in 2010 further updated the understanding of MLD pathophysiology and therapeutic advancements, which are critical for evolving treatment strategies [19]. Historically, MacFaul *et al.*, in 1982 reviewed 38 cases, laying the foundation for contemporary studies by detailing early clinical presentations and disease trajectories. Together, these studies contribute to a comprehensive understanding of MLD, reinforcing the importance of early detection and advancing therapeutic approaches [20].


Copyright © 2025. PJHS, Published by Crosslinks International Publishers LLC, USA
This work is licensed under a Creative Commons Attribution 4.0 International License.

**DOI:** https://doi.org/10.54393/pjhs.v6i2.2693

## CONCLUSIONS

Pakistan has a low incidence of Metachromatic Leukodystrophy (MLD), highlighting the need for improved diagnostic and management strategies. This case underscores the importance of early screening, particularly in consanguineous families, for timely diagnosis and intervention. The rapid neurological decline of a 30-month-old child emphasizes the necessity of genetic counseling, targeted screening, and proactive management. MRI and genetic analysis confirmed the diagnosis, demonstrating the value of integrating neuroimaging with molecular techniques. Strengthening diagnostic capabilities, multidisciplinary care, and genetic counseling in Pakistan can improve patient outcomes and contribute to the literature on MLD in low-incidence regions.

## Authors Contribution

Conceptualization: BK, SK, HBM, AQ
Methodology: BK, SK, HBM, AQ
Formal analysis: IA, AN, BK, SK, HBM, AQ
Writing, review and editing: IA, AN, BK, SK, HBM, AQ

All authors have read and agreed to the published version of the manuscript.

## Conflicts of Interest

All the authors declare no conflict of interest.

## Source of Funding

The author received no financial support for the research, authorship and/or publication of this article.

## REFERENCES

[1] Sevin C, Barth M, Wilds A, Afriyie A, Walz M, Dillon A *et al*. An international study of caregiver-reported burden and quality of life in metachromatic leukodystrophy. Orphanet Journal of Rare Diseases. 2022 Sep; 17(1): 329. doi: 10.1186/s13023-022-02501-8.

[2] Vargas SF, Morales YC, Rosell LA, Carvajal EM, Álvarez YP. Demyelinating diseases: metachromatic leukodystrophy and multiple sclerosis, a case study. Revista Cubana de Reumatología. 2022 Apr; 24(1).

[3] Mahmood A, Berry J, Wenger DA, Escolar M, Sobeih M, Raymond G *et al*. Metachromatic leukodystrophy: a case of triplets with the late infantile variant and a systematic review of the literature. Journal of Child Neurology. 2010 May; 25(5): 572-80. doi: 10.1177/0883073809341669.

[4] Shaimardanova AA, Chulpanova DS, Solovyeva VV, Mullagulova AI, Kitaeva KV, Allegrucci C *et al*. Metachromatic leukodystrophy: diagnosis, modeling, and treatment approaches. Frontiers in Medicine. 2020 Oct; 7: 576221. doi: 10.3389/fmed.2020.576221.

[5] Kehrer C, Blumenstock G, Gieselmann V, Krägeloh-mann IN, German Leukonet. The natural course of gross motor deterioration in metachromatic leukodystrophy. Developmental Medicine and Child Neurology. 2011 Sep; 53(9): 850-5. doi: 10.1111/j.1469-8749.2011.04028.x.

[6] Chang SC, Bergamasco A, Bonnin M, Bisonó TA, Moride Y. A systematic review on the birth prevalence of metachromatic leukodystrophy. Orphanet Journal of Rare Diseases. 2024 Feb; 19(1): 80. doi: 10.1186/s13023-024-03044-w.

[7] Riazuddin S, Hussain M, Razzaq A, Iqbal Z, Shahzad M, Polla DL *et al*. Exome sequencing of Pakistani consanguineous families identifies 30 novel candidate genes for recessive intellectual disability. Molecular Psychiatry. 2017 Nov; 22(11): 1604-14. doi: 10.1038/mp.2016.109.

[8] Saadi SM, Cali E, Khalid LB, Yousaf H, Zafar G, Khan HN *et al*. Genetic Investigation of Consanguineous Pakistani Families Segregating Rare Spinocerebellar Disorders. Genes. 2023 Jul; 14(7): 1404. doi: 10.3390/genes14071404.

[9] Patil SA and Maegawa GH. Developing therapeutic approaches for metachromatic leukodystrophy. Drug Design, Development and Therapy. 2013 Aug; 7: 729-45. doi: 10.2147/DDDT.S15467.

[10] Xu L, Zhong M, Wang Y, Wang Z, Song J, Zhao J *et al*. Case report: Novel arylsulfatase A (ARSA) gene mutations in a patient with adult-onset metachromatic leukodystrophy misdiagnosed as Multiple sclerosis. Frontiers in Neurology. 2021 Jan; 11: 576881. doi: 10.3389/fneur.2020.576881.

[11] Eichler F, Grodd W, Grant E, Sessa M, Biffi A, Bley A *et al*. Metachromatic leukodystrophy: a scoring system for brain MR imaging observations. American Journal of Neuroradiology. 2009 Nov; 30(10): 1893-7. doi: 10.3174/ajnr.A1739.

[12] Kubaski F, Herbst ZM, Burin MG, Michelin-Tirelli K, Trapp FB, Gus R *et al*. Measurement of sulfatides in the amniotic fluid supernatant: A useful tool in the prenatal diagnosis of metachromatic leukodystrophy. Journal of Inherited Metabolic Disease Reports. 2022 Mar; 63(2): 162-7. doi: 10.1002/jmd2.12270.

[13] Rastogi, P.K.B., Yuktika Gupta, Shourya Sharma, Pankaj Kumar Das, Pragya Sinha, Mohini Chaudhary *et al*. MRI Diagnosis in Classical Metachromatic Leukodystrophy. International Journal of Neurology and Brain Disorder. 2016 Dec; 4(1): 1-3. doi: 10.15436/2377-1348.16.1221.


Copyright © 2025. PJHS, Published by Crosslinks International Publishers LLC, USA
This work is licensed under a Creative Commons Attribution 4.0 International License.

**DOI:** https://doi.org/10.54393/pjhs.v6i2.2693

[14] Biffi A, Lucchini G, Rovelli A, Sessa M. Metachromatic leukodystrophy: an overview of current and prospective treatments. Bone Marrow Transplantation. 2008 Oct; 42(2): S2-6. doi: 10.1038/bmt.2008.275.
[15] Mallikarjun K, Bhayya DP, Singh D, Shyagali TR. Metachromatic Leukodystrophy: A Rare Case Report. Journal of Advanced Oral Research. 2011 Sep; 2(3). doi: 10.1177/2229411220110325.
[16] Politi LS, Salsano E, Biffi A. Metachromatic leukodystrophy: too frequent (mis) diagnosis?. JAMA neurology. 2018 Aug 1;75(8):1027-. doi: 10.1001/jamaneurol.2018.1515.
[17] Borges FM, Costa MJ, Carneiro ZA, Lourenço CM. Metachromatic leukodystrophy: pediatric presentation and the challenges of early diagnosis. Revista da Associação Médica Brasileira. 2020 Nov; 66: 1344-50. doi: 10.1590/1806-9282.66.10.1344.
[18] Fumagalli F, Zambon AA, Rancoita PM, Baldoli C, Canale S, Spiga I *et al.* Metachromatic leukodystrophy: a single-center longitudinal study of 45 patients. Journal of Inherited Metabolic Disease. 2021 Sep; 44(5): 1151-64. doi: 10.1002/jimd.12388.
[19] Gieselmann V, Krägeloh-Mann I. Metachromatic leukodystrophy–an update. Neuropediatrics. 2010 Feb; 41(01): 1-6. doi: 10.1055/s-0030-1253412.
[20] MacFaul R, Cavanagh N, Lake BD, Stephens R, Whitfield AE. Metachromatic leucodystrophy: review of 38 cases. Archives of Disease in Childhood. 1982 Mar; 57(3): 168-75. doi: 10.1136/adc.57.3.168.


Copyright © 2025. PJHS, Published by Crosslinks International Publishers LLC, USA
This work is licensed under a Creative Commons Attribution 4.0 International License.