



## Original Article



## Efficacy between 3-Dimensional and Champy Plates in Anterior Mandibular Fracture

Bakhtawar Laghari<sup>1</sup>, Suneel Kumar<sup>1</sup>, Zeeshan Khoso<sup>1</sup>, Hajra Rana<sup>2</sup>, Sajid Ali Majeedano<sup>3</sup> and Benish Chandio<sup>4</sup><sup>1</sup>Department of Oral and Maxillofacial Surgery, Liaquat University of Medical and Health Sciences, Jamshoro, Pakistan<sup>2</sup>Department of Oral and Maxillofacial Surgery, Shaheed Mohtarma Benazir Bhutto Institute of Trauma, Karachi, Pakistan<sup>3</sup>Department of Oral Medicine, Muhammad Dental College, Ibne Sina University, Mirpurkhas, Pakistan<sup>4</sup>Department of Oral Pathology, Muhammad Dental College, Ibne Sina University, Mirpurkhas, Pakistan

## ARTICLE INFO

**Keywords:**

Mandibular Fracture, 3-D Plate, Champys Miniplates, Efficacy

**How to Cite:**Laghari, B., Kumar, S., Khoso, Z., Rana, H., Majeedano, S. A., & Chandio, B. (2025). Efficacy between 3-Dimensional and Champy Plates in Anterior Mandibular Fracture: 3-Dimensional and Champy Plates in Anterior Mandibular Fracture. *Pakistan Journal of Health Sciences*, 6(6), 202-206. <https://doi.org/10.54393/pjhs.v6i6.2887>**\*Corresponding Author:**Bakhtawar Laghari  
Department of Oral and Maxillofacial Surgery,  
Liaquat University of Medical and Health Sciences,  
Jamshoro, Pakistan  
[drbakhtawar05@gmail.com](mailto:drbakhtawar05@gmail.com)Received Date: 17<sup>th</sup> February, 2025Revised Date: 20<sup>th</sup> May, 2025Acceptance Date: 21<sup>st</sup> June, 2025Published Date: 30<sup>th</sup> June, 2025

## ABSTRACT

Facial bone fractures or maxillofacial fractures are on the rise, specifically as a result of more road traffic accidents and sports incidents. The face is very sensitive both in terms of appearance and functionality; people who have been attacked in the face can have difficulty eating and speaking, or are extremely shy to socialize due to disfiguration. **Objective:** To compare the results of using the 3D mini plates in the treatment of the anterior mandibular fracture with Champy's mini plates. **Methods:** A Quasi-experimental study was conducted at the Department of Oral and Maxillofacial Surgery of LUMHS Jamshoro, Pakistan, in six months, and the sampling technique used was non-probability convenience sampling. Data analysis was done using statistical software SPSS version 26.0. **Results:** At the end of six weeks, the results showed that the average surgical time that was taken in the surgical procedure was shorter in Group B than in Group A, being  $(50.94 \pm 6.89)$  and  $(55.43 \pm 3.24)$  respectively;  $F=16.44$ ,  $p=0.001$ . Just as in Group B, the incidence of infection was considerably lower (8.6%) than in Group A, where it reached 28.6%, with all the differences being statistically significant ( $p=0.031$ ). **Conclusions:** 3D plates provide a biomechanically stable and versatile solution to Champy's mini plates. Because of the high strength of the material and corresponding flexibility, as well as ease of utilization, there is evidence that the 3D plates used in surgeries should be effectively employed in managing mandibular fractures.

## INTRODUCTION

Facial trauma is one of the most challenging issues in maxillofacial surgery to manage. The mandible is regarded as one of the most commonly fractured bones since it is highly protruded and has a complex shape [1]. ORIF techniques are the most preferred to treat fractures that involve the mandible. In many of the past few decades, the occurrence of traffic mishaps, violent episodes, sports and other accidents has led to an increase in cases of maxillofacial trauma. This bone, located more in the lower region of the face, is vulnerable to fracture and is among the most commonly fractured bones of the face [2].

Though new fracture management techniques help minimize the gap and improve occlusion in definitive management, the major challenge remains in helping the patient regain and return to his activities as early as possible. Factors such as the degree of fractures, the patient's dentition, and any other injuries, such as soft tissue injuries, are the basis for the choice of the fixation technique and hardware [3, 4]. Two approaches to the treatment of mandibular fracture have been developed in the process: the rigid screw osteosynthesis developed by Spiessl and the semirigid screw osteosynthesis by Champy.



Every strategy has its downside; the absolute rigidity is unfavorable when applying stress on the bone, and it takes time during the surgery. Semirigid fixation can cause certain instability in a fracture site [5, 6]. According to Michelet in 1973 and Champion in 1975, mini plate osteosynthesis has been regarded as a gold standard in the management of mandibular fractures. The field has only in the recent past integrated the use of three-dimensional (3D) titanium plates and screws for improved fracture stabilization. The plates to be used are quadrangular-shaped in three dimensions, with two crossbars connecting the two mini plates. These plates help in increasing the stability and offer better resistance to torsional loads. The main advantages of 3D plates are ease of application, high stability to torque force, and small size so that they can be considered as perspectives for mandibular fracture fixation [7-9]. When compared to the conventional mini plates and screws, this technique has certain benefits because three-dimensional plates request an average amount of plates and screws, such as four plates and six screws, for stabilization. In contrast to the mini plates used commonly in treating the mandible symphysis and parasymphysis defects, accompanied by two plates, 3D plates need only one plate for fixation. The reduction of the incorporation of foreign material makes the process less complicated and reduces operative time and the overall costs of the treatment [10-13]. Facial trauma is still a complex area of OMS, along with various techniques applied to achieve the desired results. Champy's miniplate system is widely used for treating mandibular fractures and has certain disadvantages. 3D mini plates are particularly in demand for their strength and surgery time effectiveness, which has increased in popularity in recent years.

This study aims to investigate whether, where and when the 3D miniplate system is more favorable than Champy's miniplate in reconstructive maxillofacial surgery by comparing their efficiency for the long-term advantage of the patient. To compare the effect of 3D miniplates versus Champy's miniplates fixation of anterior mandibular fractures.

## METHODS

A quasi-experimental study was organized at the Department of Oral and Maxillofacial Surgery, Liaquat University of Medical and Health Sciences (LUMHS), Jamshoro by using a non-probability consecutive sampling technique over six months (01-01-2021 to 30-6-2021) by getting approval of the research ethics committee (NO.LUMHS/REC/-996) on December 16, 2020, after obtaining the patients' written consent. The following formula was used to compute the sample size for this research:  $n = Z^2 \times p \times q / e^2$ . Where  $z=95\%$  confidence interval,  $e=5\%$  margin of error,  $p=5\%$  infection rate [7],

$q=95\%$ .  $n=1.96 \times 1.96 \times 4.8 \times 95.2 / 25$ .  $n=70$ . Hence, the study had a sample size of 70 (35 in each group). The total sample size counted was 70 (35 per group). Group A (mini-plates) =35, Group B (3D plates). The following criteria were used to define the participants for this study: Patients with anterior mandibular fracture, patients between the ages of 14 and 45 years, both sexes and those who signed informed consent. Therefore, the rationale for study inclusion involved mandibular fractures that were non-comminuted and non-infected in the symphysis and para-symphysis areas and needed ORIF. Exclusion criteria for the study involved patients with comminuted or infected mandibular fractures, geriatric patients, especially those with complete edentulism and those who did not meet all the inclusion criteria. The intervention plan entailed the ORIF method for treating such anterior mandibular fractures. According to the medical history, physical and radiological examination, and the following comprehensive investigations were done. The patients' fitness level for Surgery was also maintained at an anesthetic level for all patients undergoing ORIF. It was done under general anesthesia, and during the surgery, an arch bar was placed to allow inter-maxillary fixation before open reduction and internal fixation were made. After administering local anesthesia lidocaine with epinephrine at the operating site, trans-buccal incision was given 5mm apical to the mucogingival junction, muco-periosteal flap was reflected with careful retraction of mental nerve and fracture site was exposed, monocortical screws was used in both type of hardware used. The patient was divided into two groups using the port chit method. Group A (Mini-plates) patients in which 4-hole mini-plates were used. Group B (3D plates) consists of patients in whom 4-hole straight mini plates were used for fixation. In group A, the position of the plates aligned the horizontal link so that they were perpendicular to the fracture line of the bone, and the vertical link was parallel to the fracture line. The upper horizontal crossbar was set in the subapical position in the symphysis and parasymphysis areas. Drilling was conducted using a local anesthetic agent, following a 1.5 mm drill bit and saline solution to minimize the heat generation and the consequent damage to the cochlea. It was then fixed by using 7 mm of titanium screws. In the second group, B, a 4-holed titanium mini-plate with a 2 mm gap was contoured according to the fracture site and then applied with 7 mm titanium screws. After the plates were applied, the surgical field was washed with saline solution, and the mucoperiosteal flap was sutured with 3.0 Vicryl or silk sutures. In particular, patients were treated with antibiotics and painkillers for five days in total. Following the IMF removal, they were advised to take proper oral care, use 0.2% chlorhexidine solution to rinse the mouth, and take soft meals for six weeks. Post-operative OPG was carried out for adequacy of fracture reduction and location of plates. Follow-up intervals were carried out at 1st, 2nd, 3rd, 4th and 6th week, and outcomes between this two

hardware's were assessed in terms of infection, operative time, and outcome was recorded in the Performa at 6th week postoperatively. Statistical data analysis was done using the Statistical Package for the Social Sciences (SPSS) software version 26.0. Regarding gender, education, occupation, place of residence, and postoperative infection rate, frequency and percentage distributions were computed. A chi-squared test was used to analyze the infection data after the operation, whereas the independent samples t-test was used to analyze the differences in the operative time and infection rate, and normality of data was checked by Shapiro-Wilk's test; the level of significance taken was 0.05.

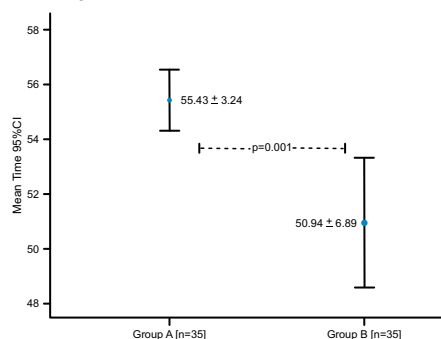
## RESULTS

Results indicate demographic information of patients where most of the patients belonged to the age group 14-25 years, followed by 26-35 and 36-45 years, respectively. The average age of  $26.14 \pm 8.11$  years was in group A and  $29.66 \pm 10.03$  years in group B. Among the gender distribution, there were 37 individuals, constituting 52.86% male, whereas 33 individuals, making up 47.14% as female. Most of the patients were urban residents (68.58%) and rural (31.42%), (Table 1).

**Table 1:** Demographic Information of Patients

Variables	Group A (%)	Group B (%)
<b>Age</b>		
Mean $\pm$ SD	$26.14 \pm 8.11$	$29.66 \pm 10.03$
14-25	18 (51.43%)	16 (45.71%)
26-35	13 (37.14%)	10 (28.57%)
36-45	4 (11.43%)	9 (25.72%)
<b>Gender</b>		
Male	18 (51.43%)	19 (54.29%)
Female	17 (48.57%)	16 (45.71%)
<b>Residence</b>		
Urban	25 (71.43%)	23 (65.71%)
Rural	10 (28.57%)	12 (34.29%)

Findings show average time taken from incision between groups 6th week postoperatively was significantly low in group B as compared to group A ( $50.94 \pm 6.89$  vs.  $55.43 \pm 3.24$ ;  $p=0.001$ ) (Figure 1).



**Figure 1:** Comparison of Average Time Taken from Incision Between Groups 6<sup>th</sup> week Post

Similarly rate of infection was also significantly lower in group B than group A (11.42% vs. 28.6%;  $p=0.031$ ) (Table 2).

**Table 2:** Comparison of Infection Rate (Final Outcome) Between Groups Within 30 Days of Post-Operatively

Infection	Group A	Group B	p-value
Yes	10 (28.6%)	4 (11.42%)	0.031
No	25 (71.4%)	31 (88.58%)	

Chi Square=4.629

Findings demonstrate a comparison of infection between groups stratified by age groups, gender & residence 6th week post-operatively, where age group 14-25 years shows a p-value of 0.05 as indicates a significant association and 26-35 ( $p=0.421$ ), followed by 36-45 ( $p=0.522$ ). Whereas gender distribution shows in male ( $p=0.056$ ) and female ( $p=0.008$ ), and rural ( $p=0.153$ ) and urban shows ( $p=0.002$ ) respectively (Table 3).

**Table 3:** Comparison of Infection Between Groups Stratified by Age Groups, Gender and Residence 6<sup>th</sup> week Post Operatively

Variables	Infection	Group A	Group B	p-value
Age Group				
14-25	Yes	6 (33.3%)	1 (6.3%)	0.05
	No	12 (66.7%)	15 (93.8%)	
26-35	Yes	3 (23.1%)	1 (10%)	0.421
	No	10 (76.9%)	9 (90%)	
36-45	Yes	1 (25%)	1 (11.1%)	0.522
	No	3 (75%)	8 (88.9%)	
Gender				
Male	Time taken	54.89 ± 2.29	51.82 ± 6.12	0.056
Female	Time taken	56.00 ± 4.00	50.11 ± 7.64	0.008

Shapiro-Wilk test results are mentioned (Table 4).

**Table 4:** Test of Normality in Data Set

Variables	Shapiro-Wilk test		
	Statistic	df	Sig.
Patient's Age	0.9927	100	0.0086
Patient's Gender	N/A	N/A	N/A
Patient's Residence	N/A	N/A	N/A

## DISCUSSION

The fractures of the mandibular angle constitute a technical problem. Moreover, different management strategies have been discussed in the literature. The study found that in managing unfavorable mandibular angle fractures, 3D plate osteosynthesis is as effective as the double mini-plate technique. He stated that both techniques provide adequate stability for correct fracture union, allow for functional occlusion, and enable early return to work. In large and severe displacement or fracture cases, mini-plate adjustment and placement require some time and are technically challenging. However, 3D applications of locking plates offer more efficiency and ease of deployment in operations compared with the

current conventional plate systems. This type of plate is not only less time-consuming and easy to apply but also economical and shows better biomechanical properties. Sikora *et al.*, introduced mini plates with 3D dimensions, stating that any structurally stable construction has quadrilateral geometrical stability [18]. This structure enables a thinner plate thickness, which is normally about 1mm. There are four common specifications: the basic sizes are a 2X2-hole square flat plate, a 3X2 or a 4X2-hole rectangular flat plate. At the same time, these are described as "3D mini-plates," and most are not genuine 3D objects. They only ensure fracture stability by opposing forces in the fracture section in the form of shear force, bending moment and twisting moment. Nonetheless, while several writers have reported on the benefits of using 3D mini plates in the management of mandibular fractures, they are not as popular as expected. For instance, a mailed survey of 104 AO/ASIF surgeons established that only 6% use this plate in their practice. A single study comparing the differences in operative time to conventional mini-plates and 3D mini-plates was conducted, which showed that the former took an average of  $1.88 \pm 0.38$  hours as opposed to  $1.61 \pm 0.27$  hours for the 3D mini-plates. Another study of mandibular anterior fractures, single plate for fixation of recommended the use of a single plate for anterior mandibular fracture fixation using a 3D Titanium mini-plate as an effective method as that to Champy's two-mini-plate system. This technique also provides sufficient stability, needs relatively little working time, and is somehow related to the reduced rate of infections over the mini-plate systems [18, 19]. In this study, the average time taken from incision to the completion of the procedure at the sixth postoperative week, Group B 3D plates have recorded the least time as compared to Group A mini-plates  $< \text{Chi}^2(p)=0.001$ . Also, the level of infection rate was significantly lower in the second group as compared to the first one ( $p=0.031$ ). Based on the findings of this experiment and literature findings made by Feledy *et al.*, Jain *et al.*, and Zix *et al.*, it is clear that the use of 3D plates decreases average operating time [20-22]. These include greater ease of application, simplified incorporation of the bone, ability to stabilize the superior and inferior borders in one procedure, which makes the 3D plates associated with little morbidity and infection. The infection rates noted by various investigators on 3D plates have been as follows: Feledy *et al.*, 9% (2 out of 22 patients) [20] and Zix *et al.*, [22] (0 out of 20 patients). This protocol says that the mobility of the fractured segments contributes to postoperative infections, and this is contrary to the findings of the other two protocols. Because infection is one of the most frequent complications in mandibular fractures, improving the stability of the plates might reduce it. This study also

concludes that there are advantages of employing 3D plates in the management of the anterior mandibular fractures, particularly concerning better three-dimensional stability, less morbidity, and infection rates. One of the threats of these plates could be the extra volume of the implant material due to the fact that supplementary vertical bars are intended to prevent torque forces from acting on the implant.

## CONCLUSIONS

This plate was 3D in shape with a strong mid-section but thin edges, thereby allowing easy reduction and stabilization at the superior and inferior aspects of the fracture site. It offers three-dimensional stability at the fracture site. It appears to be an easy solution to conventional mini plate champs.

## Authors Contribution

Conceptualization: BL

Methodology: BL, SK, SAM, BC

Formal analysis: BL

Writing review and editing: ZK, HR

All authors have read and agreed to the published version of the manuscript

## Conflicts of Interest

All the authors declare no conflict of interest.

## Source of Funding

The author received no financial support for the research, authorship and/or publication of this article.

## REFERENCES

- [1] Barde DH, Mudhol A, Ali FM, Madan RS, Kar S, Ustaad F. Efficacy of 3-dimensional plates over Champys miniplates in mandibular anterior fractures. *Journal of International Oral Health*. 2014 Feb; 6(1): 20.
- [2] Liu Y, Wei B, Li Y, Gu D, Yin G, Wang B et al. The 3-dimensional miniplate is more effective than the standard miniplate for the management of mandibular fractures: a meta-analysis. *European Journal of Medical Research*. 2017 Dec; 22: 1-0. doi: 10.1186/s40001-017-0244-2.
- [3] Budhreja NJ, Shenoi RS, Badjate SJ, Bang KO, Ingole PD, Kolte VS. Three-dimensional locking plate and conventional miniplates in the treatment of mandibular anterior fractures. *Annals of Maxillofacial Surgery*. 2018 Jan; 8(1): doi: 73-7. 10.4103/ams.ams\_175\_17.
- [4] Khalifa M, Essa E, Elshall M. Management of fractures of anterior mandible with different fixation methods: A single institutional experience. *Egyptian Journal of Oral and Maxillofacial Surgery*. 2018 Apr; 9(2): 45-54. doi: 10.21608/omx.2018.19564.
- [5] Kanala S, Gudipalli S, Perumalla P, Jagalanki K, Polamarasetty PV, Guntaka S, et al. Aetiology,



- prevalence, fracture site and management of maxillofacial trauma. *The Annals of the Royal College of Surgeons of England*.2021Jan;103(1):18-22.doi: 10.1308/rcsann.2020.017.
- [6] Kannari L, Marttila E, Toivari M, Thorén H, Snäll J. Paediatric mandibular fracture a diagnostic challenge? *International Journal of Oral and Maxillofacial Surgery*.2020 Nov; 49(11): 1439-44. doi: 10.1016/j.ijom.2020.06.008.
  - [7] Pal US, Singh RK, Dhasmana S, Das S, Das SK. Use of 3-D plate in displaced angle fracture of mandible. *craniomaxillofacial trauma and reconstruction*.2013 Mar; 6(1): 25-9. doi: 10.1055/s-0032-1332211.
  - [8] Ribeiro-Junior PD, Senko RA, Momesso NR, Izidoro JH, Padovan LE, Viswanath A. Occlusal instability results in increased complication rates after treatment of mandibular fractures. *Journal of Oral and Maxillofacial Surgery*.2020 Jul; 78(7): 1163-e1. doi: 10.1016/j.joms.2020.02.013.
  - [9] Mohammad OA, Ashour EM, Hassanein FA. Evaluation of condylar position in anterior mandibular fractures using 3 dimensional miniplate osteosynthesis versus conventional miniplates: randomized clinical trial. *Journal of Cranio-Maxillofacial Surgery*.2022Jan; 50(1): 61-9. doi: 10.1016/j.jcms.2021.09.014.
  - [10] Khalil S, Khamis H, Kauke M, Iizuka T, Safi AF. Three-dimensional osteosynthesis plates for the surgical treatment of mandibular fractures. *Journal of Craniofacial Surgery*.2021Nov;32(8):e728-35doi: 10.1097/SCS.00000000000007709.
  - [11] Aurora JK, Tiwari S, Dubey KN, Tandon P, Chauhan H, Srivastava AP, Saxena M. Conventional versus 3D plates for mandibular anterior region fractures: A comparative study. *The Traumaxilla*.2019 Dec; 1(2-3): 49-56. doi: 10.1177/26323273211070523.
  - [12] Elnasser A, Gamal H, Elfar AM, Hussien MM. Three-dimensional locking plate and conventional mini plates in the treatment of mandibular anterior fractures. *Al-Azhar Journal of Dental Science*. 2022 Apr;25(2):157-62.doi:10.21608/ajdsm.2020.48431.1132.
  - [13] Farmand M, Dupoirieux L. The value of 3-dimensional plates in maxillofacial surgery. *Revue de stomatologie et de chirurgie maxillo-faciale*.1992 Jan; 93(6): 353-7.
  - [14] Gear AJ, Apasova E, Schmitz JP, Schubert W. Treatment modalities for mandibular angle fractures. *Journal of Oral and Maxillofacial Surgery*.2005May; 63(5): 655-63. doi: 10.1016/j.joms.2004.02.016.
  - [15] McLeod NM, Keenan M. Towards a consensus for classification of mandibular condyle fractures. *Journal of Cranio-Maxillofacial Surgery*.2021Apr; 49(4): 251-5. doi: 10.1016/j.jcms.2021.01.017.
  - [16] Kozakiewicz M, Zieliński R, Konieczny B, Krasowski M, Okulski J. Open rigid internal fixation of low-neck condylar fractures of the mandible: mechanical comparison of 16 plate designs. *Materials*.2020Apr; 13(8): 1953. doi: 10.3390/ma13081953.
  - [17] Adhikari M, Bhatt K, Yadav R, Mandal J, Bhutia O, Roychoudhury A. Fixation of subcondylar fractures of the mandible: A randomised clinical trial comparing one trapezoidal plate with two miniplates. *International Journal of Oral and Maxillofacial Surgery*.2021Jun;50(6):756-62.doi:10.1016/j.ijom.2020.10.009.
  - [18] Sikora M, Chęciński M, Sielski M, Chlubek D. The Use of 3D Titanium Miniplates in Surgical Treatment of Patients with Condylar Fractures.*Journal of Clinical Medicine*.2020Sep;9(9):2923.doi:10.3390/jcm9092923.
  - [19] Thapliyal S, Mowar A, Bansal V. Comparison between conventional titanium miniplates and indigenous detachable custom made 3D titanium plates (VAS 3D bone plate) for fixation of mandibular fracture in mental foramen region: A randomized clinical trial and finite element analysis. *Journal of Maxillofacial and Oral Surgery*.2022 Mar: 1-8. doi: 10.1007/s12663-020-01397-w.
  - [20] Feledy J, Caterson EJ, Steger S, Stal S, Hollier L. Treatment of mandibular angle fractures with a matrix miniplate: a preliminary report. *Plastic and Reconstructive Surgery*.2004 Dec; 114(7): 1711-6. doi: 10.1097/01.PRS.0000142477.77232.F7.
  - [21] Jain MK, Manjunath KS, Bhagwan BK, Shah DK. Comparison of 3-dimensional and standard miniplate fixation in the management of mandibular fractures. *Journal of Oral and Maxillofacial Surgery*.2010Jul; 68(7): 1568-72. doi: 10.1016/j.joms.2009.07.083.
  - [22] Zix J, Lieger O, Iizuka T. Use of straight and curved 3-dimensional titanium miniplates for fracture fixation at the mandibular angle.*Journal of Oral and Maxillofacial Surgery*.2007Sep;65(9):1758-63.doi: 10.1016/j.joms.2007.03.013.