



Original Article



Effect of Supra Choroid Triamcinolone Acetate On Intraocular Pressure

Syed Sohail Ahmed Shah^{*}, Uzma Haseeb¹, Nasir Ahmed¹, Israr Ahmed¹, Shoaib Ahmed¹ and Shahid Hussain Shah¹
¹Department of Ophthalmology, AL Ibrahim Eye Hospital, Karachi, Pakistan

ARTICLE INFO

Keywords:

Corticosteroids, Intraocular Pressure, Triamcinolone, Supra-Choroidal Space

How to Cite:
 Shah, S. S. A., Haseeb, U., Ahmed, N., Ahmed, I., Ahmed, S., & Shah, S. H. (2025). Effect of Supra Choroid Triamcinolone Acetate On Intraocular Pressure: Supra Choroid Triamcinolone Acetate for Intraocular Pressure. *Pakistan Journal of Health Sciences*, 6(1), 152–156. <https://doi.org/10.54393/pjhs.v6i1.2087>
***Corresponding Author:**
 Syed Sohail Ahmed Shah
Department of Ophthalmology, AL Ibrahim Eye Hospital, Karachi, Pakistan
shlbkhr@gmail.com
Received Date: 15th August, 2024Acceptance Date: 21st January, 2025Published Date: 31st January, 2025

ABSTRACT

Intraocular pressure is a critical parameter in maintaining the physiological function of the eye. Dysregulation of Intraocular pressure can lead to ocular pathologies. **Objective:** To evaluate change in intraocular pressure after supra-choroidal triamcinolone acetate use. **Methods:** This prospective interventional study was carried out at the vitreo-retina Department of AL Ibrahim Eye Hospital Karachi, ISRA Postgraduate Institute of Ophthalmology for six months from July to December 2023. Adult patients attending the vitreoretinal Outpatient Department with resistant macular oedema were included. Intraocular pressure readings at 1 week, 4 weeks, 8 weeks and 12 weeks were recorded and compared with baseline values by applying One-way ANOVA keeping the p-value of <0.05 as statistically significant. Data were analyzed using SPSS v 22.0. **Results:** Among all, 21 (46.67%) cases received injections to the right eye and 24 (53.33%) cases to the left eye. The mean intraocular pressure before injection was 12.07 ± 2.14 mmHg. At three months' post-injection, the mean intraocular pressure was 13.60 ± 5.2 mmHg. For the right eye; the mean pre-injection intraocular pressure was 12.38 ± 1.96 mmHg. Three months' post-injection, the mean intraocular pressure was 13.43 ± 5.59 mmHg ($p < 0.001$). For the left eye; the mean pre-injection intraocular pressure was 11.79 ± 2.28 mmHg while three months' post-injection, the mean intraocular pressure was 13.75 mmHg ± 4.96 ($p = 0.06$). **Conclusions:** It was concluded that supra-choroidal triamcinolone injections increase intraocular pressure but stabilized over time. These findings support earlier trials and add to the evidence of this therapy's efficacy and safety.

INTRODUCTION

The pharmacologic features of the suprachoroidal space (SCS) for ocular drug delivery, particularly triamcinolone acetonide (TA), have been the subject of several investigations [1, 2]. Compared to traditional intravitreal injection, this method yielded a much higher drug concentration in the choroid and outer retina. Injecting suprachoroidal triamcinolone acetonide (SCTA) reduces the primary side effects of steroids, which are cataracts and increased intraocular pressure (IOP) because the medication is insignificantly exposed to structures in the anterior region [2]. Supra-choroid is a unique passage in ocular treatment with steroids wherein as drug concentration decreases, it also results in decreased incidence of cataract formation and intraocular pressure elevation [3]. Triamcinolone acetonide treats thyroid eye illness, complex chalazia, iridocyclitis, scleritis, macular oedema, and allergic eye disorders. Ocular and systemic

corticosteroids have been linked to high IOP, glaucoma, and cataracts [4]. Triamcinolone acetonide possesses strong anti-inflammatory and anti-edematous properties. Hence it has been commonly used in the treatment of uveitis diabetic macular edema and other inflammatory retinal disorders [5-7]. Thus, it allows a new route of drug administration owing to possible localized high-concentration drug formulations, which could be utilized with minimal systemic exposure [8, 9]. Supra-choroidal triamcinolone acetonide, although used most frequently for uveitic macular edema has demonstrated beneficial effects on IOP [10]. However, as with other corticosteroids, suprachoroidal triamcinolone can induce steroid-induced IOP elevation; therefore, its use in IOP control primarily for glaucoma is not a first-line option and should be used carefully given the high risk of increased IOP [11]. For glaucoma patients, this is very concerning because



elevated IOP can make the condition worse [12]. A novel strategy for the treatment of DME the administration of supra-choroidal triamcinolone has just evolved. One distinct anatomical benefit of administering medication to the back of the eye through the suprachoroidal area is the reduction of risks connected with intravitreal injections. [13]. The effectiveness of several treatment options for diabetic macular edema (DME) has been highlighted in numerous research, which has provided insight into prospective strategies to improve anatomical and functional results [13, 14]. Supra-choroidal triamcinolone users must monitor their IOP. Treating IOP elevation with topical IOP-lowering medications typically works [15]. Suprachoroidal triamcinolone acetate may reduce IOP elevation risk compared to other corticosteroid administration techniques, but it is not used to manage IOP in glaucoma [16]. To understand its function and efficacy in this environment, careful observation and investigation are needed. The current study will assess intraocular pressure following supra-choroidal triamcinolone acetate administration. Intraocular pressure (IOP) is a critical parameter in maintaining the physiological function of the eye. Dysregulation of IOP can lead to ocular pathologies such as glaucoma, a leading cause of irreversible blindness. Triamcinolone acetate, a corticosteroid, is widely used in ophthalmology due to its potent anti-inflammatory properties. It is commonly administered through various routes, including intravitreal injections, for conditions like diabetic macular edema, uveitis, and retinal vein occlusion. However, corticosteroids are known to elevate IOP, posing a risk for steroid-induced glaucoma. Recent advancements in drug delivery have introduced the suprachoroidal route as a minimally invasive alternative for targeted drug administration. This route enables precise delivery to the posterior segment of the eye while minimizing systemic absorption and anterior segment exposure. Despite the theoretical advantages, there is limited empirical evidence regarding the safety profile of triamcinolone acetate when administered via the suprachoroidal route, particularly its effect on IOP.

This study aims to evaluate change in intraocular pressure after supra-choroidal triamcinolone acetate use.

METHODS

A prospective interventional study was done at the Vitreo-retina Department of Al Ibrahim Eye Hospital Karachi, ISRA Postgraduate Institute of Ophthalmology for a period of six months (IRB Approval Number ATMC/IERC/13th/01-2023)/10) from July to December 2023 using non-probability consecutive sampling. Calculation of sample size was done using Open Epi online sample size calculator keeping mean intraocular pressure at baseline 14 ± 5 mmHg, 95 % confidence interval and 80 % power [17]. Adult

patients after getting informed written consent, attending the Vitreoretinal Out Patient Department (OPD) with resistant macular edema who had already undergone 3 intra-vitreous anti-Vascular endothelial growth factor (VEGF) injections one month apart but with no effect on macular edema and patients >18 years of age were included in the study. Patients having Intraocular pressure IOP of more than 20 mmHg, cataract, macular ischemia (documented on Fundus Fluorescein Angiography (FFA)), ocular hypertension and renal disease were excluded in addition to patients that lately had intra-vitreous triamcinolone or posterior sub-Tenon triamcinolone acetate injection within 3 months were also excluded. Resistant macular edema was identified as macular edema which was not successfully responding to loading dose of any of 3 anti-VEGF injections administered at a month's time difference. No change in best corrected visual acuity with the Snellen chart and Central macular thickness measured with Optical Coherence Tomography (OCT) was regarded as no improvement. The included patients were administered suprachoroidal triamcinolone acetate injection. Pre-injection IOP was measured using an applanation tonometer. A 1cc insulin syringe was used along with a 30 gauge (BD Insulin syringe with a BD ultrafine Needle; Becton, Dickinson and Company, New Jersey, United States). The injection used was triamcinolone acetate (TA) 40mg/ml (Kenakort A by GlaxoSmithKline Brentford, Middlesex, TW9 9GS, United Kingdom) which was injected via the 24-gauge intravenous catheter and 1 cc needle was then removed from cannula and cut so that only 1 mm insulin needle was out from cannula edge. After taking all aseptic measures, 0.1ml triamcinolone acetate (TA) was injected at 3.5 mm from the limbus in the infra-temporal or supra-temporal quadrant. 4 mg of 0.1ml TA was infused into the supra-choroidal area after labelling via insertion into the sclera by perpendicularly placed needle and blade facing back at a distance of 3.5 mm from the limbus. The needle was gradually detached and a cotton tip applicator was applied to ensure nominal reflux at the injection site. The surgery was followed by the instillation of moxifloxacin eye drops into the cornea. 3 months' strict follow-up was done for all the patients and follow-ups were planned at 1, 4, 8 and 12 weeks. Intraocular pressure was checked and marked at every follow-up on decided proforma. Data were analyzed using SPSS v 22.0. Discrete variables were presented as frequencies and percentages while continuous variables were presented as means and standard deviation. Intraocular pressure (IOP) readings at 1 week, 4 weeks, 8 weeks and 12 weeks were recorded and compared with baseline values by applying One-way ANOVA keeping the p-value of <0.05 statistically significant.

RESULTS

A total of 45 injections were administered in this research. The majority 26 (57.8%) were female and 19 (42.2%) were male. The finding demonstrates the frequency distribution of injections administered between the right and left eyes among the 45 subjects, 21 (46.67 %) to the right eye and 24 (53.33 %) to the left eye (Figure 1).

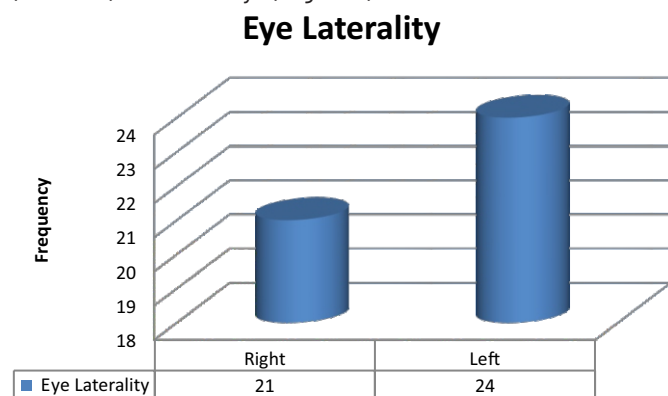


Figure 1: Frequency of Side of Eye Injected Upon (n=45)

Further finding shows intra-ocular pressure (IOP) measurement at different intervals: pre-injection, one week, one, two and at three months' post-injection. Mean IOP before injection was 12.07 ± 2.14 mmHg, ranging from 10 to 18 mmHg. One week after the injection, the mean IOP increased to 13.71 ± 3.8 mmHg and a range of 10 to 30 mmHg. At one month, the mean IOP slightly decreased to 13.22 ± 4.43 mmHg, a range of 10-36 mmHg. Two months' post-injection, the mean IOP was 13.33 ± 4.5 mmHg, range of 10-30 mmHg. Finally, at three months' post-injection, the mean IOP was 13.60 ± 5.2 mmHg and a range from 10 to 36 mmHg (Table 1).

Table 1: Mean \pm Standard Deviation of Intra-Ocular Pressure Before and Three Month After Injection (n=45)

Time of Checking	Intra-ocular Pressure (mmHg)		
	Mean \pm SD	Minimum	Maximum
Pre-Injection	12.07 ± 2.14	10	18
One Week	13.71 ± 3.8	10	30
One Month	13.22 ± 4.43	10	36
Two Months	13.33 ± 4.5	10	30
Three Months	13.60 ± 5.2	10	36

The association between pre- and post-injection intra-ocular pressures was assessed for both the right and left eyes, (Table 2).

Table 2: Association Between Pre and Post-Injection Follow-Ups (n=45)

Laterality of Eye		n	Mean \pm SD	p-value
Right	Pre-Injection	21	12.38 ± 1.96	<0.001
	One Week		14 ± 4.35	<0.001
	One Month		13.52 ± 5.72	<0.001
	Two Months		13.24 ± 4.75	<0.001

	Three Months		13.43 ± 5.59	<0.001
Left	Pre-Injection	24	11.79 ± 2.28	0.006
	One Week		13.46 ± 3.32	0.09
	One Month		12.96 ± 2.97	0.05
	Two Months		13.42 ± 4.39	0.05
	Three Months		13.75 ± 4.96	0.06

DISCUSSION

The current research investigated the effects of supra-choroidal triamcinolone injections on intraocular pressure (IOP) over three months. The main results were the post-injection changes in intraocular pressure (IOP) measured at various time points. Results showed a significant increase in IOP one week after injection, with subsequent stabilization over the next three months. Additionally, similar results were seen in other explorations as well [18-20]. The results of our study confirmed previous conclusions on corticosteroids and intraocular pressure. One week following the injection, we noted that there was a significant increase in the average IOP compared to levels before injection (mean 12.07 mmHg vs mean 13.71 mmHg), just as Yeh *et al.*, had done in one of their studies. This first increment matches with the findings of Yeh *et al.*, which implies an average increase of nearly about 3.4 mm Hg at week one [21]. The possible reasons behind such an increase of IOP post-operatively could be attributed to increased resistance in the trabecular meshwork, transient inflammatory reaction post-injection leading to localized swelling, direct mechanical effect of the injection itself and insensitivity to corticosteroid activity including genetic factors. For instance, Zhang *et al.*, showed that intraocular pressure rose prominently one-month post-injection but began to decrease thereafter. Our results reflect this trend, with a mean IOP of 13.22 mm Hg at one month following injection, representing a slight decrease from its peak value at one week. This trend is consistent with those of Zhang *et al.*, work where there are more substantial decreases after higher maximums [22]. Likewise, Abdelshafy *et al.*, found that suprachoroidal triamcinolone injections caused significant IOP rise. Their findings were not far off from our own, showing an increase in average IOP after a month by as much as 3.8 mmHg while our increase was around 3.15 mm Hg from the baseline before injection. This consistency underscores the reproducibility of our results, supporting the notion that suprachoroidal triamcinolone injections typically cause an initial IOP rise that stabilizes subsequently [23]. Another feature in our study is the difference in IOP changes between the two eyes. The 21 cases of the right eye showed significant IOP increases at all follow-up points, with p-values consistently below 0.001. Conversely, the left eye had a major increase only pre-injection (p=0.006) while other subsequent alterations were not as significant (p-

values ranging from 0.05 to 0.09). This indicates a probable difference in response depending on eye laterality and therefore calls for further investigations directed towards establishing the causes of such differences. Our findings have great clinical significance. It is possible to regulate the intraocular pressure (IOP) elevation that occurs after an injection since it gradually decreases over time and stays within a range that is considered to be acceptable by the majority of patients from a medical standpoint [23-25].

CONCLUSIONS

It was concluded that intraocular pressure (IOP) spiked after supra-choroidal triamcinolone injections but stabilized after a while. These results are in line with other studies and add to the growing body of information about the effectiveness and safety of this therapy method. Further research is needed to deepen our understanding and improve treatment procedures so that patients can have the best possible results.

Authors Contribution

Conceptualization: SSAS

Methodology: SSAS, IA, SHS

Formal analysis: SSAS

Writing review and editing: UH, NA, SA

All authors have read and agreed to the published version of the manuscript

Conflicts of Interest

All the authors declare no conflict of interest.

Source of Funding

The author received no financial support for the research, authorship and/or publication of this article.

REFERENCES

- [1] Campochiaro PA, Wykoff CC, Brown DM, Boyer DS, Barakat M, Taraborelli D et al. Supra-choroidal Triamcinolone Acetonide for Retinal Vein Occlusion: Results of the Tanzanite Study. *Ophthalmology Retina*. 2018 Apr; 2(4): 320-8. doi: 10.1016/j.oret.2017.07.013.
- [2] Habet-Wilner Z, Noronha G, Wykoff CC. Supra-choroidally Injected Pharmacological Agents for the Treatment of Chorio-Retinal Diseases: A Targeted Approach. *Acta Ophthalmologica*. 2019 Aug; 97(5): 460-72. doi: 10.1111/aos.14042.
- [3] Wykoff CC, Khurana RN, Lampen SI, Noronha G, Brown DM, Ou WC et al. Supra-Choroidal Triamcinolone Acetonide for Diabetic Macular Edema: The HULK Trial. *Ophthalmology Retina*. 2018 Aug; 2(8): 874-7. doi: 10.1016/j.oret.2018.03.008.
- [4] Bhattacharyya S, Hariprasad SM, Albini TA, Dutta SK, John D, Padula WV et al. Supra-choroidal Injection of Triamcinolone Acetonide Injectable Suspension for the Treatment of Macular Edema Associated with Uveitis in the United States: A Cost-Effectiveness Analysis. *Value in Health*. 2022 Oct; 25(10): 1705-16. doi: 10.1016/j.jval.2022.07.008.
- [5] Yousef MS, Abd Elhafez YA, Farag MH. Assessment of Supra-Choroidal Injection of Triamcinolone Acetonide in Cases of Diabetic Macular Edema. *International Journal of Medical Arts*. 2021 Apr; 3(2): 1384-9. doi: 10.21608/ijma.2021.55079.1230.
- [6] Thomas J, Kim L, Albini T, Yeh S. Triamcinolone Acetonide Injectable Suspension for Suprachoroidal Use in The Treatment of Macular Edema Associated with Uveitis. *Expert Review of Ophthalmology*. 2022 May; 17(3): 165-73. doi: 10.1080/17469899.2022.2114456.
- [7] Kim TK, Shin HY, Kim SY, Lee YC, Lee MY. Factors Influencing Intra-vitreous Bevacizumab and Triamcinolone Treatment in Patients with Diabetic Macular Edema. *European Journal of Ophthalmology*. 2017 Nov; 27(6): 746-50. doi: 10.5301/ejo.5000974.
- [8] Rahman S, Tayyab H, Siddiqui MR. Supra-Choroidal Triamcinolone Acetonide Injection to Treat Macular Edema: A Review. *Journal of Vitreo Retinal Diseases*. 2024 Nov; 8(6): 699-708. doi: 10.1177/24741264241275271.
- [9] Fatima M, Abbas S, Sajjad T. Efficacy and Safety of Triamcinolone Acetonide Injection in Supra-Choroidal Space. *Biological and Clinical Sciences Research Journal*. 2023; 290. doi: 10.54112/bcsrj.v2023i1.290.
- [10] Fung S and Syed YY. Supra-Choroidal Space Triamcinolone Acetonide: A Review in Uveitic Macular Edema. *Drugs*. 2022 Sep; 82(13): 1403-10. doi: 10.1007/s40265-022-01777-1.
- [11] Ghazanfar AS, Khowaja AH, Tayyab H. Effect of Supra-Choroidal Triamcinolone On Intraocular Pressure: A Systematic Review and Meta-Analysis. *Therapeutic Advances in Ophthalmology*. 2024 Feb; 16: 25158414241228671. doi: 10.1177/25158414241228671.
- [12] Roberti G, Oddone F, Agnifili L, Katsanos A, Michelessi M, Mastropasqua L et al. Steroid-Induced Glaucoma: Epidemiology, Pathophysiology, and Clinical Management. *Survey of Ophthalmology*. 2020 Jul; 65(4): 458-72. doi: 10.1016/j.survophthal.2020.01.002.
- [13] Singer MA, Merrill P, Yeh S, Hall C, Kapik B, Ciulla TA. Supra-Choroidal Triamcinolone Acetonide Versus Rescue Therapies for the Treatment of Uveitic Macular Oedema: A Post Hoc Analysis of PEACHTREE. *Clinical and Experimental Ophthalmology*. 2022 Jan; 50(1): 23-30. doi: 10.1111/ceo.14024.
- [14] Jung JH, Chae JJ, Prausnitz MR. Targeting Drug Delivery Within the Supra-Choroidal Space. *Drug Discovery Today*. 2019 Aug; 24(8): 1654-9. doi: 10.1016/j.drudis.2019.07.008.

- 10.1016/j.drudis.2019.03.027.
- [15] Aslam M, Nazir T, Haq RI, Asghar A, Nadeem S, Obaid N. Efficacy of Supra-Choroidal Versus Intra-vitreous Triamcinolone Acetonide in Refractory Macular Edema; A Quasi-experimental study. *Pakistan Armed Forces Medical Journal*.2024 Oct1; 74(5): 1365. doi: 10.51253/pafmj.v74i5.10818.
- [16] Wu KY, Fujioka JK, Gholamian T, Zaharia M, Tran SD. Supra-Choroidal Injection: A Novel Approach for Targeted Drug Delivery. *Pharmaceutics*.2023 Sep; 16(9): 1241. doi: 10.3390/ph16091241.
- [17] Tayyab H, Ahmed CN, Sadiq MA. Efficacy and Safety of Supra-Choroidal Triamcinolone Acetonide in Cases of Resistant Diabetic Macular Edema. *Pakistan Journal of Medical Sciences*.2020 Jan; 36(2): 42. doi: 10.12669/pjms.36.2.1194.
- [18] Wan CR, Muya L, Kansara V, Ciulla TA. Supra-Choroidal Delivery of Small Molecules, Nanoparticles, Gene and Cell Therapies for Ocular Diseases. *Pharmaceutics*. 2021 Feb; 13(2): 288. doi: 10.3390/pharmaceutics13020288.
- [19] Zakaria YG, Salman AG, Said AM, Abdelatif MK. Supra-Choroidal Versus Intra-Vitreous Triamcinolone Acetonide for the Treatment of Diabetic Macular Edema. *Clinical Ophthalmology*.2022 Mar: 733-46. doi: 10.2147/OPTH.S351853.
- [20] Ateeq A, Majid S, Memon NA, Hayat N, Somroo AQ, Fattah A. Supra-Choroidal Injection of Triamcinolone Acetonide for Management of Resistant Diabetic Macular Oedema. *The Journal of the Pakistan Medical Association*.2023 Feb; 73(2): 239-44. doi: 10.47391/JPMA.2239.
- [21] Yeh S, Khurana RN, Shah M, Henry CR, Wang RC, Kissner JM et al Efficacy and Safety of Supra-choroidal CLS-TA for Macular Edema Secondary to Noninfectious Uveitis: Phase 3 Randomized Trial. *Ophthalmology*.2020 Jul; 127(7): 948-55. doi: 10.1016/j.ophtha.2020.01.006.
- [22] Zhang DD, Che DY, Zhu DQ. A Simple Technique for Supra-Choroidal Space Injection of Triamcinolone Acetonide in the Treatment of Macular Edema. *International Journal of Ophthalmology*.2022; 15(12): 2017. doi: 10.18240/ijo.2022.12.18.
- [23] Abdelshafy Tabl A, Tawfik Soliman T, Anany Elsayed M, Abdelshafy Tabl M. A Randomized Trial Comparing Supra-choroidal and Intra-vitreous Injection of Triamcinolone Acetonide in Refractory Diabetic Macular Edema Due to Epiretinal Membrane. *Journal of Ophthalmology*.2022; 2022(1): 7947710. doi: 10.1155/2022/7947710.
- [24] Munir MS, Rehman R, Nazir S, Sharif N, Chaudhari MZ, Saleem S. Visual Outcome after Suprachoroidal Injection of Triamcinolone Acetate in Cystoid Macular Edema of Different Pathology. *Pakistan Journal of Medical and Health Sciences*.2022 May; 16(05): 164-. doi: 10.53350/pjmhs22165164.
- [25] Ali BM, Azmeh AM, Alhalabi NM. Supra-Choroidal Triamcinolone Acetonide for the Treatment of Macular Edema Associated with Retinal Vein Occlusion: A Pilot Study. *BioMed Central Ophthalmology*. 2023 Feb; 23(1): 60. doi: 10.1186/s12886-023-02808-5.